

## The occasional burr hole

Keith MacLellan MD

abridged from CJRM 1998; 3(4): 223-2

---

### Equipment

You either have it or you will have to improvise. Formally you would have a penetrator and a burr. Lacking either you can substitute a half inch drill bit (Canadian Tire Part #54-8032-8). Sterilise it and you will now call it an instrument. ([Fig. 1](#)). You will also need light, suction, cautery, a prep tray, self retractors or rakes, sutures, gelfoam, penrose drain and possibly some rongeurs.

### Procedure

Avoid the orbit and temporal artery. In adults two to three finger breadths above the top of the ear and two in front will place you above the floor of the zygoma. ([Fig. 2](#))

Remember trephination was developed in the stone age so relax. Shave and prep the site. Make a vertical 3 cm incision down to the periostium. Retract immediately to minimise bleeding from the skin edge. ([Fig. 3](#))

Drill with the penetrator through the outer table ([Fig. 4](#)). Switch to the burr for the inner table (or proceed with the drill letting up on the pressure) ([Fig. 5](#))

Use soft suction tip to evacuate the haematoma. Insert a penrose drain, apply a sterile dressing, the patient wakes up and you are done ([Fig. 6](#)).

If you encounter arterial bleeding and cautery and gelfoam (or temporalis muscle) is insufficient and you expect prolonged transport, use cervical rongeurs to nibble back on the skull to expose the bleeder.

Abridged version © 2005 Society of Rural Physicians of Canada, used with permission




Fig 1 Several Trephiners

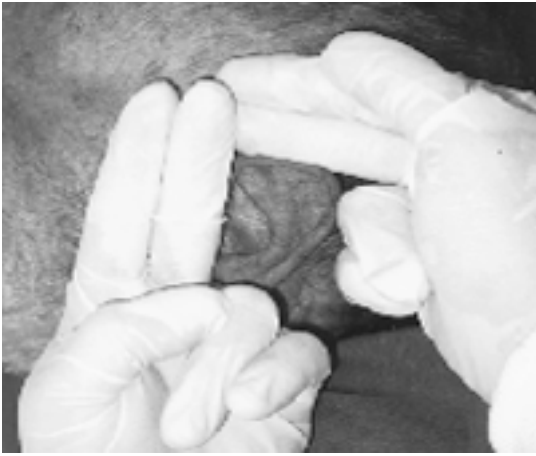

Fig 2 Plan to drill above the floor of the zygoma!

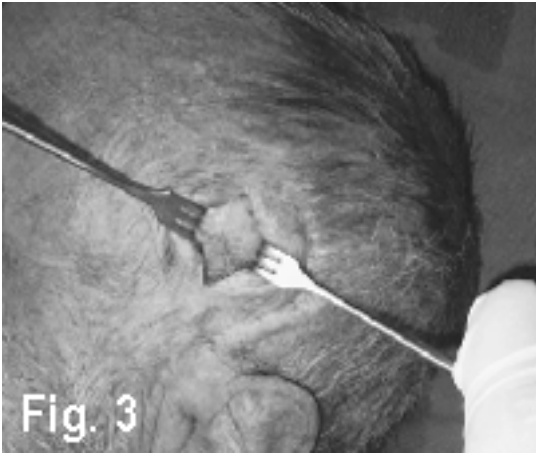


Fig 3 Apply immediate tension on wound edge

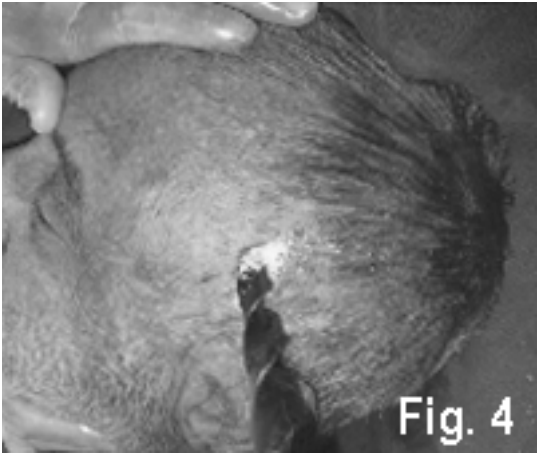


Fig 4 Drill through the outer table

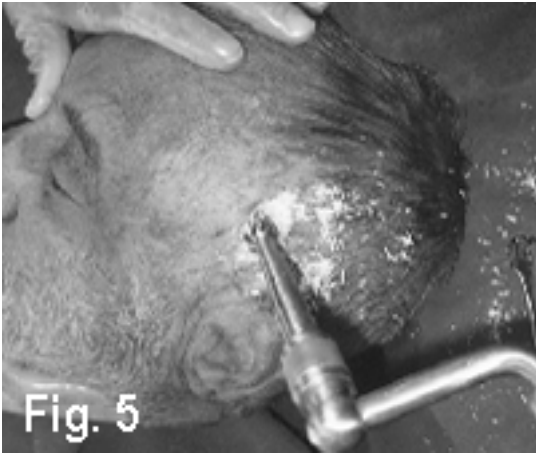

Fig 5 Switch to burr for inner table

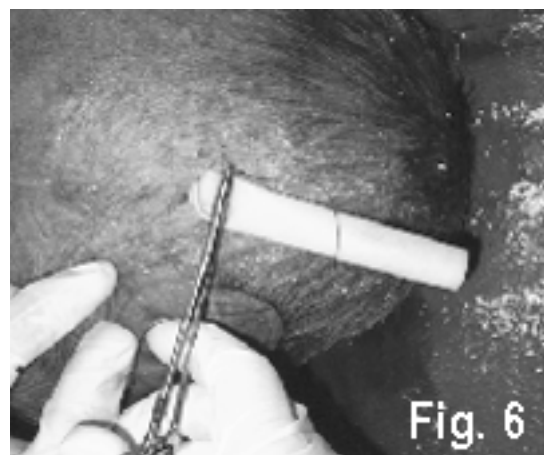


Fig 6 After evacuating the haematoma suture in a drain