



THE PRACTITIONER LE PRATICIEN

Country cardiograms case 26

Keith MacLellan, MD
Shawville, Que.

Correspondence to:
Dr. Keith MacLellan,
PO Box 609, Shawville
QC J0X2Y0

This article has been peer
reviewed.

This 34-year-old farmer presents to your rural hospital with a history of syncope lasting 5 seconds. Onset occurred after 5 minutes of heavy manual work rapidly forking manure. He does not recall any chest pain. He has a family history of sudden death, but no other risk factors and no past history of cardiac problems. His vital signs and physical exam-

ination are normal, apart from a short, flow-type 2/6 systolic murmur at the left sternal border with no radiation. His cardiac enzymes, troponins and chest x-ray are also normal (see Fig. 1).

For the Answer, see page 266.

Competing interests: None declared.

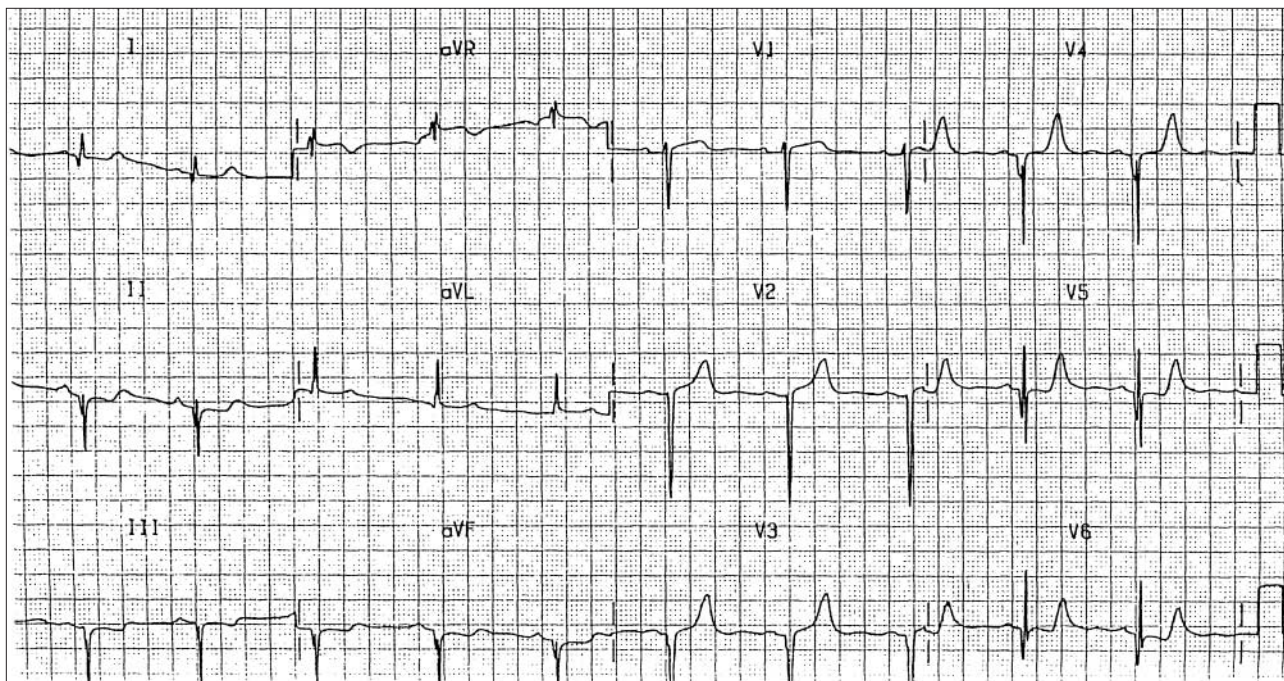


Fig. 1. Results of chest x-ray performed shortly after patient arrived at the hospital. ECG courtesy of Dr. Martin Green, Ottawa Heart Institute, Ottawa, Ont.