



THE PRACTITIONER LE PRATICIEN

Country cardiograms case 27

Charles Helm, MD
Tumbler Ridge, BC

Correspondence to:
Dr. Charles Helm,
Box 1690, Tumbler Ridge
BC V0C 2W0;
drchelm@pris.bc.ca

This article has been peer
reviewed.

A 20-year-old woman arrived by ambulance at the emergency department of a rural British Columbia hospital. She had been found with a decreased level of consciousness beside an empty bottle of amitriptyline pills (it is thought that she took over 5000 mg). Her estimated weight is 50 kg.

Her pulse is recorded at 140 beats/min, with a fair volume. Blood pressure is recorded at 133/81 mm Hg.

Her breathing is laboured and slow. While attention is being paid to ABCs and the resuscitation commences, a 12-channel ECG is obtained (Fig. 1). Soon afterward, the patient begins to have seizures.

What is your analysis, and are there any implications for treatment?

For the Answer, see page 191.

Competing interests: None declared.

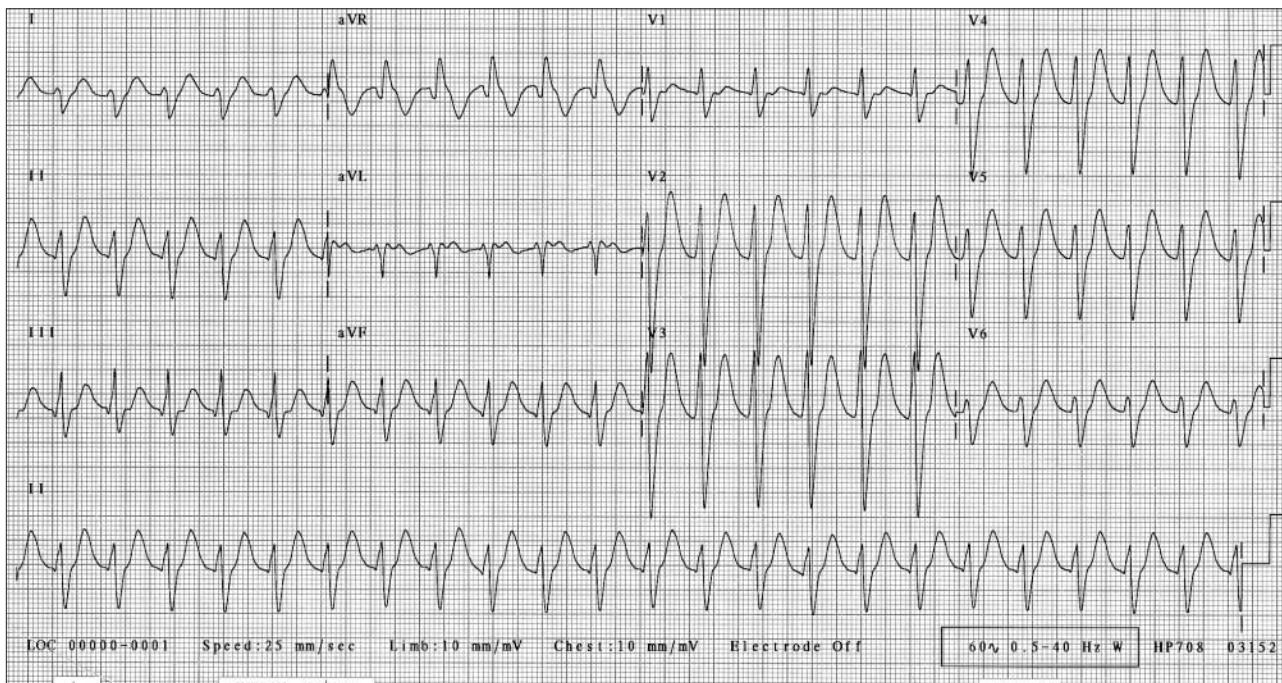


Fig. 1. Results of first ECG, taken during resuscitation of the patient.