



# THE PRACTITIONER LE PRATICIEN

## Country cardiograms case 27: Answer

Charles Helm, MD  
Tumbler Ridge, BC

**T**he situation described is a challenge for a lone emergency department physician practising in a remote area. Although tricyclics are no longer the first-line treatment for depression, they are still commonly used to treat conditions such as chronic pain syndromes and fibromyalgia. Overdose from tricyclics is therefore less commonly seen than in previous decades (they were introduced in the 1960s) but will continue to occur.

If the estimated dosage and patient weight are correct, it is clear that complications can be expected from this potentially lethal overdose. Close and prolonged attention will need to be paid to seizure management, fluid balance, electrolyte balance, and alkalinization

of serum pH. Airway control with assisted ventilation will likely be needed. Into this mix must be thrown the potential for significant cardiotoxicity and dangerous arrhythmias.

Illustrated in the Question section (page 171) and repeated here, Figure 1 displays a regular wide-complex tachycardia, rate 139 beats/min, with QRS duration 0.14 seconds. P waves cannot be identified. There is no evidence of dissociated P waves, capture beats or fusion beats to “rule in” ventricular tachycardia. QRS morphology shows deep S waves in many leads, with some degree of concordance in precordial leads V1–V6. Significant right axis deviation is present, with axis in the 4th quadrant, of 200 degrees. Tall T waves are present.

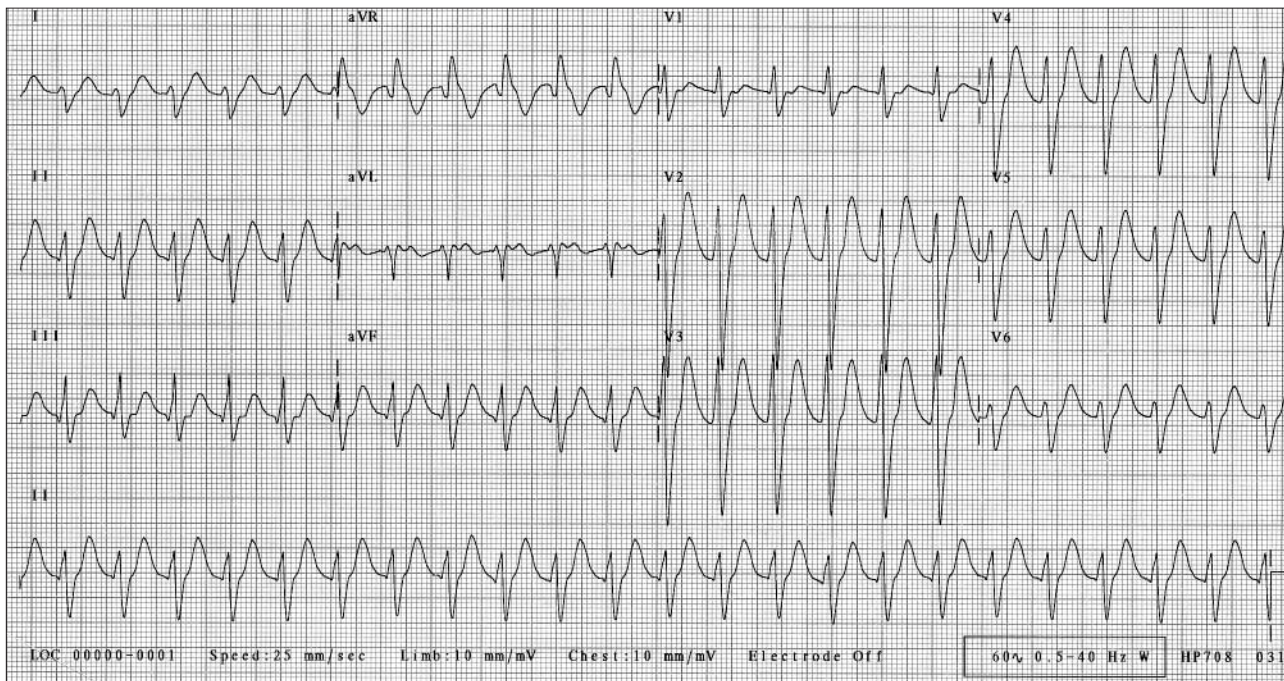


Fig. 1. Results of first ECG, taken while resuscitation of the patient was being initiated.

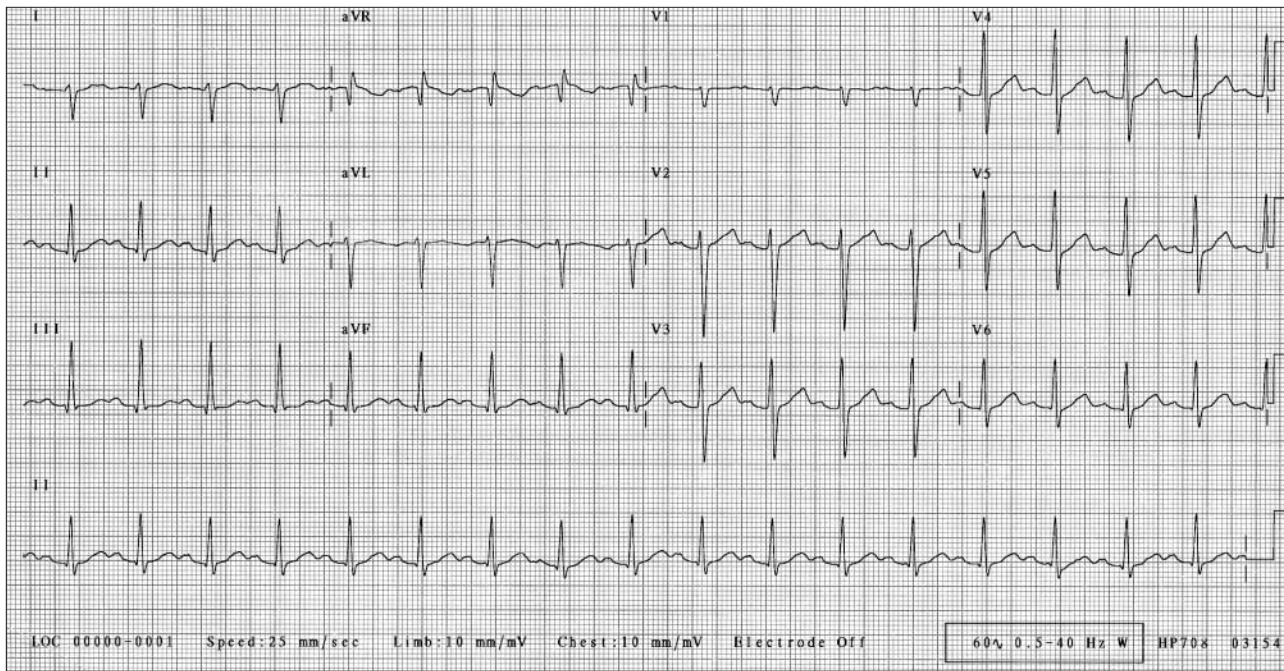


Fig. 2. Results of ECG taken 4 hours after resuscitation procedures were begun. ECG displays sinus tachycardia, heart rate 105 beats/min, first degree A-V block with P-R interval 0.21 seconds, QRS duration 0.10 seconds, and QTc of 0.46 seconds.

This case illustrates the importance of knowing the context in interpreting an ECG. The differential diagnosis for a case of regular wide-complex tachycardia includes ventricular tachycardia and supraventricular (including sinus) tachycardia with bundle-branch block or aberrancy. Without the above history, the approach might prevail of assuming ventricular tachycardia until there is good reason to think otherwise, even though the rate of 139 beats/min is slower than would be expected for this diagnosis, and the degree of QRS widening is likewise less than could be expected.

In the context of the history provided, however, awareness of the common ECG effects of tricyclic overdose is useful. The most common arrhythmia is sinus tachycardia due to an anticholinergic effect. The PR interval is typically prolonged, and non-specific QRS widening from delay in the bundle-branch system is common, with an associated axis shift to the right. T wave abnormalities are common.

If it is accepted that normal P waves could be concealed in the preceding tall T waves, it is apparent that these common tricyclic overdose effects can account for all the ECG abnormalities seen in Fig-

ure 1 and are a more likely explanation than ventricular tachycardia.

The lonely emergency physician could therefore conclude that there are enough other life-threatening issues to deal with urgently in this case, without reaching immediately for the paddles or cardiac drugs. Ongoing monitoring and follow-up ECGs would be essential because of the real possibility of more serious blocks and arrhythmias such as ventricular tachycardia, torsade de pointes, and ventricular fibrillation.

In this case, heart rate, QRS duration, axi, and T wave amplitude slowly returned toward normal as resuscitation proceeded. P waves, previously concealed in the preceding T waves, became apparent (Fig. 2).

Following intensive resuscitation, including prolonged ventilation, this patient made a successful recovery.

For the Question, see page 171.

**Acknowledgement:** The author is indebted to Dr Mario Halenar for clinical details on this case.