



THE PRACTITIONER LE PRATICIEN

Country cardiograms case 29

Charles Helm, MD,
CCFP

Tumbler Ridge, BC

Correspondence to:
Dr. Charles Helm,
Box 1690, Tumbler Ridge
BC V0C 2W0;
drchelm@pris.bc.ca

*This article has been peer
reviewed.*

A 52-year-old male patient was brought to a rural British Columbia emergency department with a 1-hour history of chest pain. An ECG was taken as soon as possible (Fig. 1).

What is the diagnosis, and what further study should be done?

For the Answer, see page 54.

Competing interests: None declared.

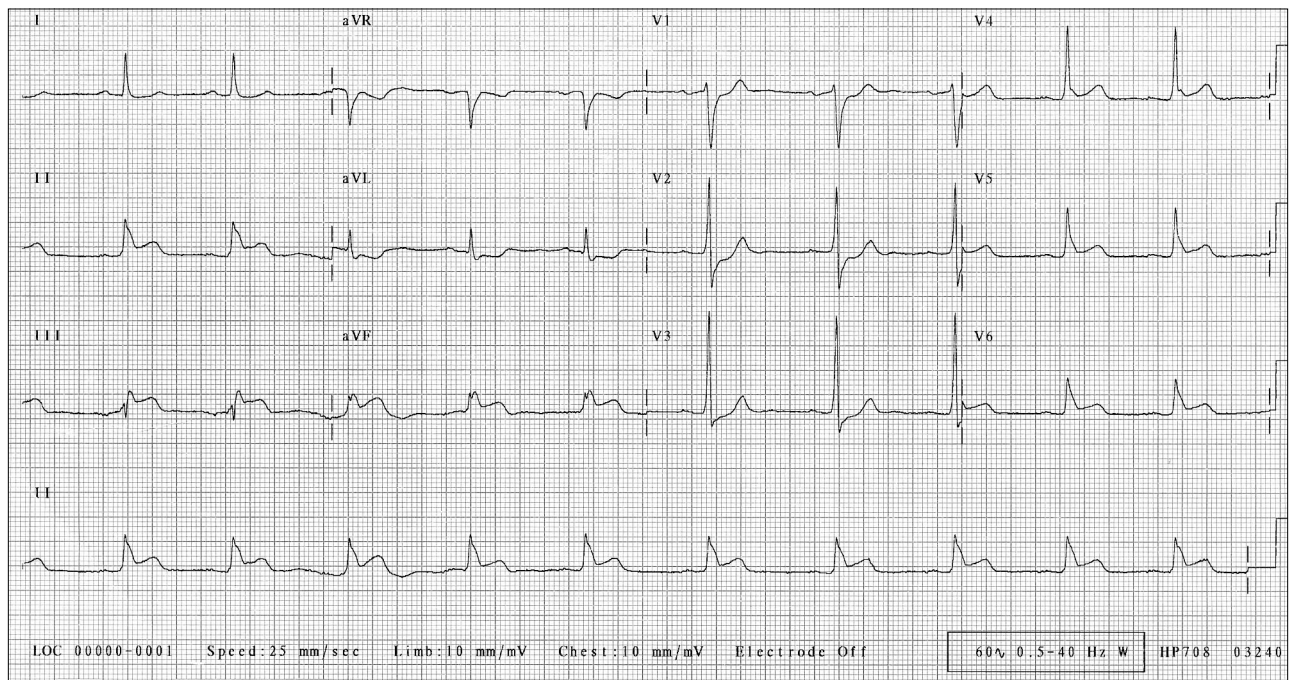


Fig. 1. Results of the first ECG, taken shortly after the patient's arrival in the emergency department.