



THE PRACTITIONER LE PRATICIEN

Country cardiograms case 30

Charles Helm, MD,
CCFP

Tumbler Ridge, BC

Correspondence to:
Dr. Charles Helm,
Box 1690, Tumbler Ridge
BC V0C 2W0;
drhelm@pris.bc.ca

*This article has been peer
reviewed.*

A sixty-seven-year-old woman is brought to the emergency department of a rural British Columbia hospital with symptoms of weakness and a sensation that her heart is racing. The following tracing is obtained (Fig. 1).

What is your ECG diagnosis?

For the Answer, see page 133.

Competing interests: None declared.

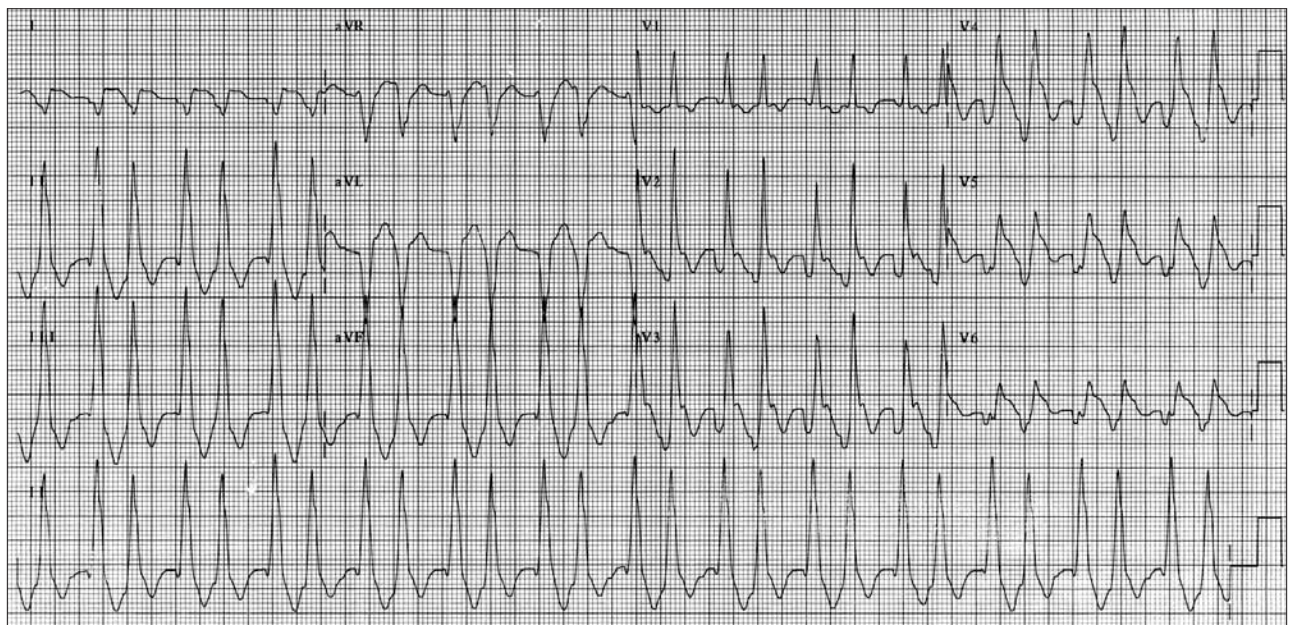


Fig. 1. Results of the ECG taken shortly after the patient's arrival in the emergency department.