



# THE PRACTITIONER LE PRATICIEN

## The occasional shoulder reduction

Len Kelly, MD

Sioux Lookout, Ont.

Correspondence to:

Len Kelly

Box 489

Sioux Lookout ON

P8T 1A8

*This article has been peer reviewed.*

**T**he shoulder is the most mobile joint in the body. With this relative instability, it is no surprise that it is the most common joint dislocation seen in the emergency department.<sup>1</sup> With an annual incidence of 17 per 100 000 people,<sup>2</sup> a rural physician group serving 10 000–20 000 patients may encounter only several each year.

Reduction methods can be confusing, if only because there are multiple options. In this article I offer what pearls there are and I review the 10 reduction methods in the literature. Most emergency physicians will need their chosen approach as well as one or 2 backup methods.

### GENERAL CONSIDERATIONS

Some general comments are in order. A dislocated shoulder is neither time sensitive nor limb threatening. Several methods include only gentle movements and claim to require little sedation.<sup>3–6</sup> These methods may work well on the calm and relatively pain-free patient who may have suffered an atraumatic dislocation. Reduction methods that use traction on the sore shoulder will require analgesia or sedation. The simplest medication to consider is 10–20 mL of 1% xylocaine injected into the joint space. If the patient is deeply sedated, he or she requires constant monitoring, oxygen and saturation monitoring, intravenous access and airway capabilities at hand. I use intravenous narcotics and always have naloxone (Narcan) drawn up in a syringe. An old chart can sometimes outline prior reduction successes if the patient is one of the

25% of people who present with a recurrent dislocation.

In some cases, the shoulder cannot be reduced in the emergency department and requires total muscle paralysis in the operating room. The reduction in the emergency department may fail and referral may be necessary; rarely, an open reduction is needed.<sup>7</sup>

Successful reductions may be accompanied by a satisfying “pop,” but more often are not. It is therefore helpful to have a clinical sense of the defect below the deltoid where the humeral head should sit, as the shoulder may relocate quietly with one’s initial efforts.

### HISTORY

Most shoulder dislocations are anterior (97%), resulting from external rotation and abduction.<sup>8</sup> This commonly occurs from a fall on an outstretched arm or a sporting injury.<sup>9</sup> People who have recurrent dislocations, especially the young and active, may eventually need elective referral for operative repair after their third or fourth episode.

The rare posterior dislocation may be due to anteriorly directed force or it may be secondary to seizure activity.<sup>10,11</sup>

### X-RAYS

Most clinicians are familiar with the typical anteroposterior (AP) view of the anterior dislocation. Rare posterior dislocations are easily picked up by adding a routine trans-scapular view to the AP view. The most common accompanying fracture is an avulsion fracture of the greater tuberosity of the humerus. These fractures (as well as HillSachs and Bankhart lesions) do not

affect the decision or approach to reduction.<sup>12</sup> However, if a surgical humeral neck fracture or dislocation is present, refer this patient on, as this can be fraught with complications and may require open reduction.<sup>12</sup>

## PHYSICAL EXAM

Typically, the patient is unable to touch his or her good shoulder with the hand of the affected arm. Before reduction, assess and document the neurovascular status of the limb: radial pulse and nerve, and auxiliary nerve. The auxiliary nerve innervates the deltoid muscle, which initiates abduction in the healthy subject. While this cannot be tested in the patient with a dislocation, the sensory "cadet patch" of skin over the lower deltoid is easily tested for touch perception. Such common (8%) nerve palsies are documented before a reduction and are followed afterward with conservative management.<sup>15</sup> They generally resolve on their own and they often require physiotherapy, prolonged sling application and may need electromyograph studies at the 3-month time frame, if ongoing. Since the auxiliary nerve shares the posterior aspect of the brachial plexus with the radial nerve, it too should be tested with wrist extension and sensation to the dorsum of the hand. The latter are very rare injuries.

## TREATMENT

Reduction methods have evolved since ancient times and often have a clinician's name associated with them. None are cast in stone and they may involve variations of previous approaches. Basically, we are trying to apply force across the joint in a somewhat predictable manner to attain reduction. Generally, traction, leverage and rotation are involved. In the elderly, forced rotation and leverage must be used cautiously as they may predispose an elderly patient to a humeral fracture. Leverage is used in the Kocher<sup>6</sup> and Hippocratic<sup>14</sup> methods. Traction is used in Milch,<sup>8,15</sup> Spaso,<sup>4</sup> Stimson<sup>1</sup> and Matsen's traction counter-traction<sup>14,16</sup> approaches. Rotation is common to many, but is the mainstay of scapular manipulation<sup>3,15</sup> and of the modified Kocher.<sup>17</sup>

Treatment should not exhaust the clinician or the patient. Simple rotation methods can be attempted without medication. They need to be done very, very slowly and should be the first attempt at reduction, with a cooperative patient.

I have often been called in after a failed attempt and have used a traction counter-traction method with a healthy dose of analgesia on board. I begin with a careful description of this method, as it works in most situations. For purposes of discussion, let's assume that the patient's left shoulder is dislocated.

## EQUIPMENT LIST

- Oxygen and saturation monitor
- IV, running
- Intubation equipment available
- Midazolam 0.015–0.05 mg/kg (1–5 mg)
- Fentanyl 1–3 µg/kg (50–300 µg)
- Naloxone 0.4 mg

## MATSEN'S TRACTION COUNTER-TRACTION METHOD

When this method was originally described in the 1940s, 2 attendants tied themselves to the patient and actively pulled in opposite directions.<sup>14</sup> I have modified this method so only one physician is needed and no active muscles are required.

### Step 1

The patient is supine, sedated, monitored, has nasal prongs and is tied to the far side of the stretcher with a triple knotted sheet. The knots should be visible so the clinician can ensure that they are not slipping, or the ends should be clamped with a snap (Fig. 1).

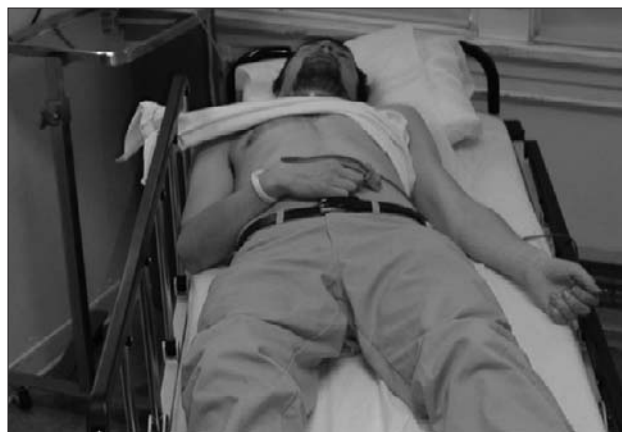

Fig. 1. Step 1 of Matsen's traction counter-traction method in which the patient is tied to the stretcher.

### Step 2

The physician then attaches a triple knotted sheet to his waist and loops it over the patient's flexed

elbow. The physician keeps his own elbows fully extended and maintains the patient's elbow flexion to ensure it does not jack-knife open. Essentially, the physician is passively pushing the patient's wrist away with his locked arms and applying traction to the humerus with his body weight. Physicians of slight build may not develop enough force to use this method successfully (Fig. 2).

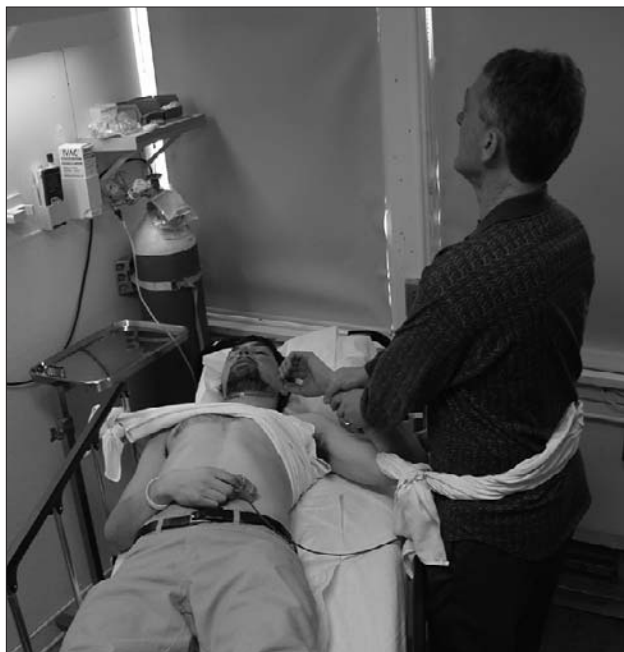

Fig. 2. Step 2 of Matsen's traction counter-traction method. The physician is attached to the patient using a bed sheet.

### Step 3

With the patient sedated to the point where he or she does not respond to conversational stimuli, the physician applies traction passively, by beginning to "water ski," applying weight to the traction sheet. If the patient rouses, more analgesia or sedation and time are required. (Fig. 3)

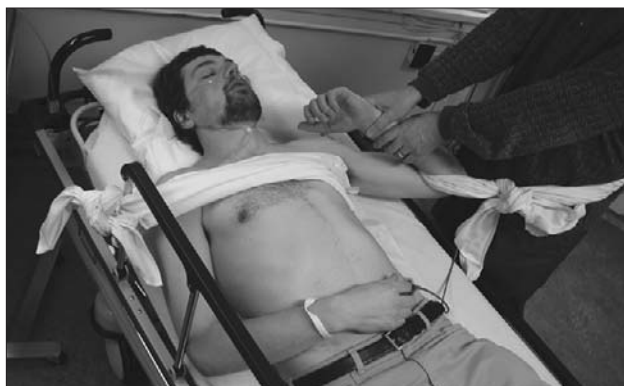

Fig. 3. The physician applies traction as part of Matsen's method.

### Step 4

By applying an increasing angle of "water skiing," more traction force is applied (Fig. 4). The physician can also do some gentle back and forth rotation of the arm to facilitate reduction. The object is to "hang there" and wait for the spasming muscles to relax. This may take several minutes. Since the patient is sedated, post reduction x-rays are taken with a single AP view using a portable machine. Once reduction is verified, I administer Narcan (naloxone) so that the patient awakens from his or her narcotic sedation and requires less monitoring.

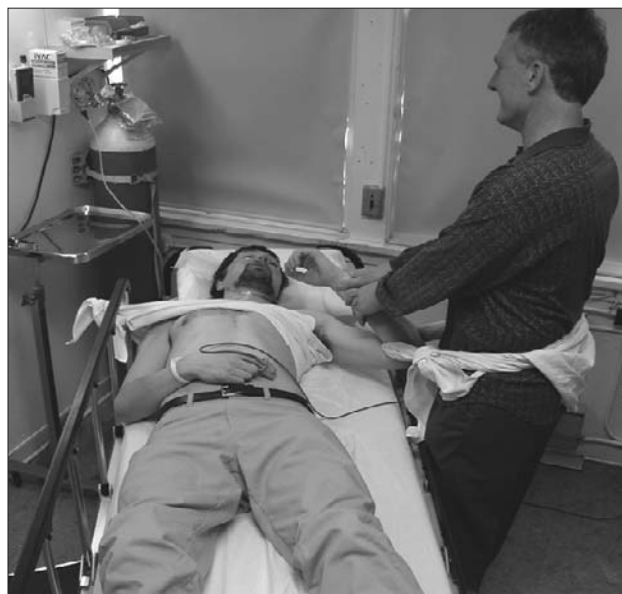

Fig. 4. The physician "water skiing" (Matsen's method).

## KOCHER AND MODIFIED OR PARTIAL KOCHER

This is a widely taught and successful method with several important theoretical variations. Since leverage is used in the classic Kocher manoeuvre, care should be taken when using this method in the elderly as there is a risk of fracture. The patient is usually lying supine.

The original method was described in 1870 without traction on the humerus.<sup>6</sup>

### Step 1

The first step consists of external rotation of the adducted arm, held at the patient's side (in hitch-hiking position)

### Step 2

The patient's elbow is then slid along the chest to midline (levering the humerus against the thorax).

### Step 3

The patient's palm is internally rotated to touch the opposite shoulder. The original translation from German added in humeral traction at the elbow, which is how it is now commonly described and performed.<sup>12</sup> Traction at the elbow may or may not assist the reduction.<sup>6</sup>

A newer version of this method includes only the external rotation performed very slowly (5 min or more) by the patient or physician, with the elbow stabilized at the patient's side. This method is done without humeral traction and without moving the elbow position at all<sup>17</sup> (Fig. 5, Fig. 6, Fig. 7, Fig. 8, Fig. 9). External rotation is performed around the fixed elbow to 70–80 degrees. Some methods suggest that you should be successful at this point if the rotation has been very gradual (more than 5 minutes) and if the patient is calm and comfortable.<sup>17</sup> (If external rotation is the extent of the manipulation, this can be done in the seated position.)

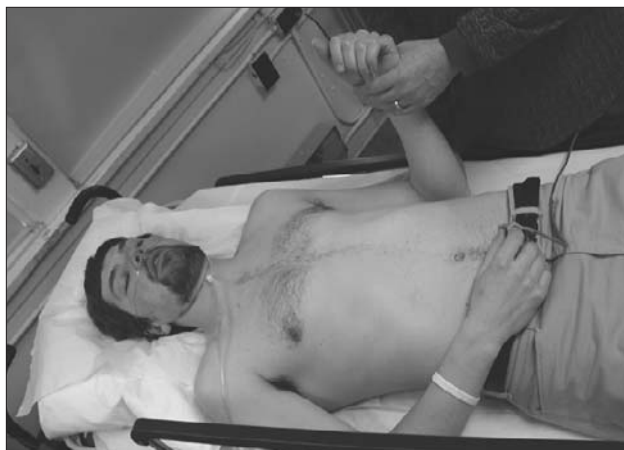

Fig. 5. Initial position for a classic or modified Kocher.

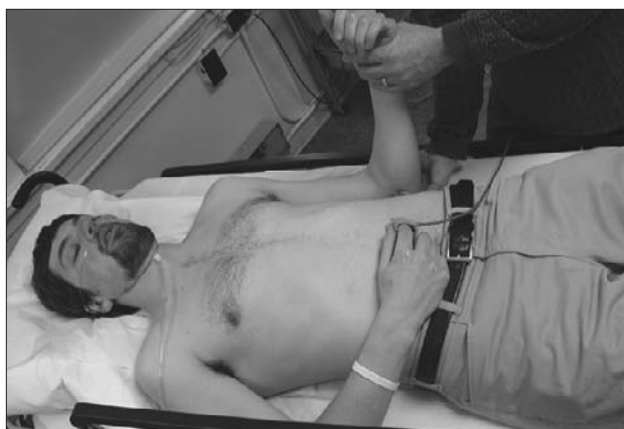

Fig. 6. Traction at the elbow is not part of original Kocher method, but is commonly performed and may require increased analgesia.

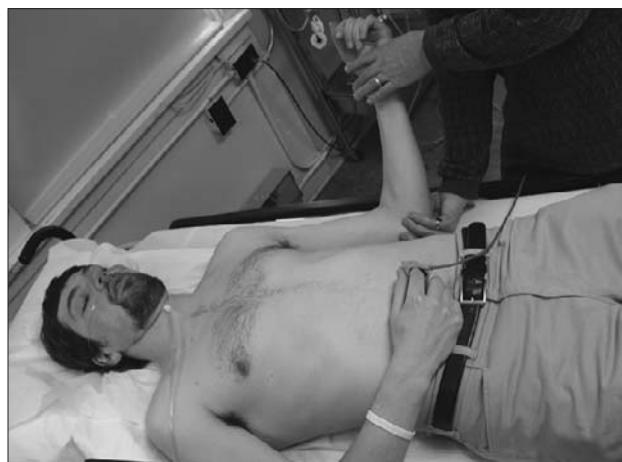

Fig. 7. External rotation around the fixed elbow to 70–80 degrees (very slowly) as part of the Kocher method.

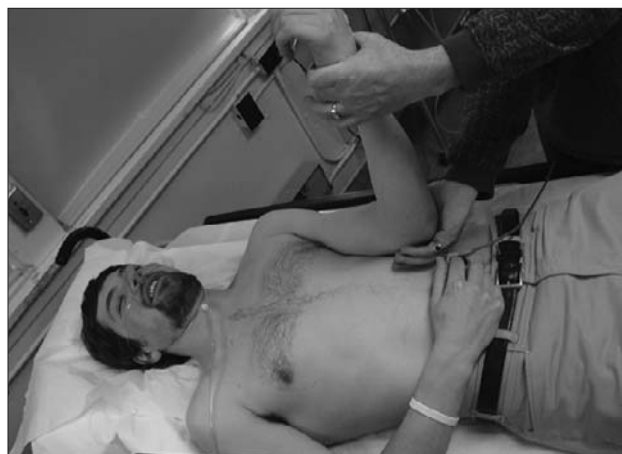

Fig. 8. In the Kocher method, the physician brings the patient's elbow across the chest, which levers the humerus against the thorax.

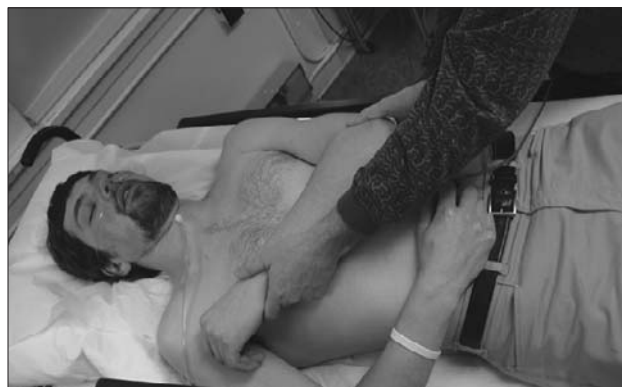

Fig. 9. Internal rotation across the chest follows the movement of the patient's elbow across the chest (Kocher method).

### STIMSON'S METHOD

In 1905, Stimson<sup>1</sup> described hanging 10 lb from a prone patient's arm and letting the shoulder self-reduce. This method does not allow for ready observa-

tion of the patient's airway and may not be useful in the inebriated or sedated patient. The Stimson method can be combined with scapular rotation<sup>5,15</sup> (Fig. 10).

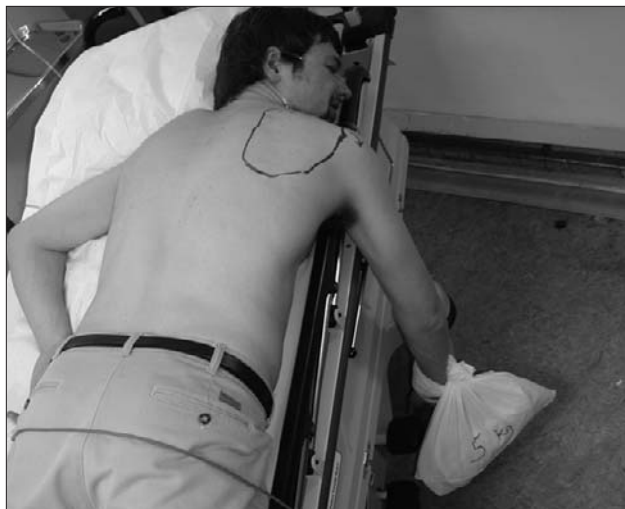

Fig. 10. Stimson's method in which a 5 kg weight is attached to the patient's arm (the patient should not hold the weight).

### SCAPULAR ROTATION METHOD

Described in 1977,<sup>18</sup> scapular rotation attempts to replace the ball in the socket by rotating the scapula (the socket) so that it "picks up" the inferiorly displaced humeral head. As we can see from the previous photo (Fig. 10), passive Stimson's traction or active physician traction can be combined with scapular manipulation.

#### Step 1

The bottom of the scapula is identified and the physician's thumbs push it sharply medially while the top of the scapula is stabilized (Fig. 11). Several attempts may be needed.

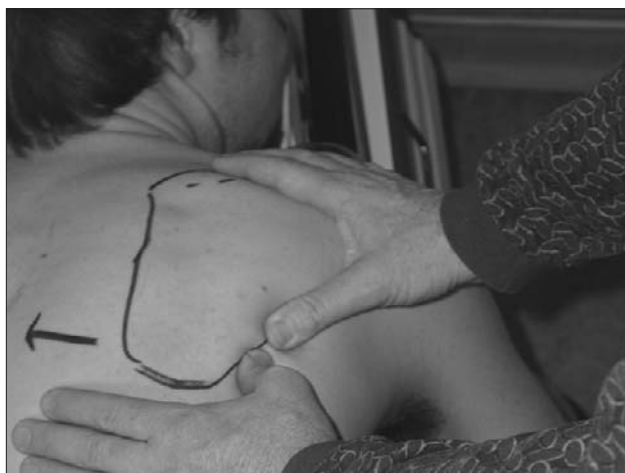


Fig. 11. Identification of the scapula.

#### Step 2

Scapular rotation can be combined with active traction by a sole clinician or by an assistant (Fig. 12).

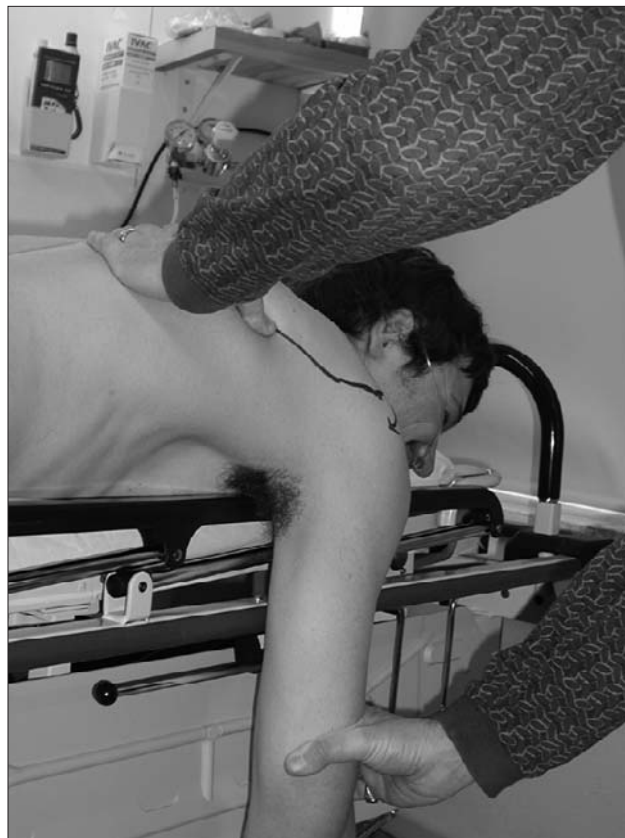

Fig. 12. Scapular rotation method may be accompanied by traction of the arm.

#### Step 3

Scapular rotation can also be performed in the seated position with the bed at 90 degrees (Fig. 13).

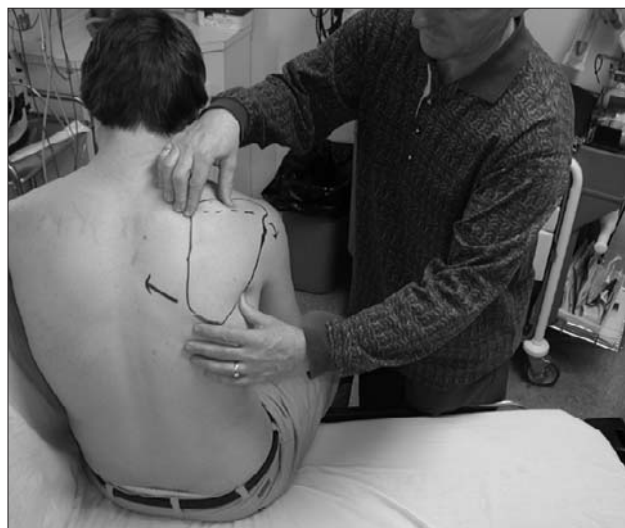

Fig. 13. Scapular rotation performed in a seated position with the bed at 90 degrees.

#### Step 4

This method can be performed with or without downward humeral traction (Fig. 14).

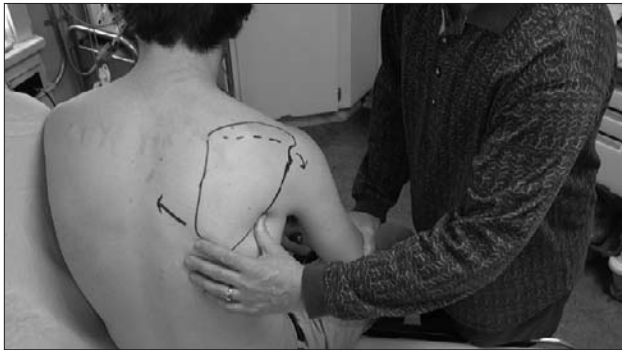

Fig. 14. Scapular rotation method in which the physician applies downward traction to the patient's arm.

#### MILCH METHOD

Essentially, the patient has his or her arm brought slowly to the overhead baseball-throwing position. The patient's elbow can be flexed or extended.<sup>8,15</sup> The physician applies a small amount of traction on the arm while stabilizing the dislocated humeral head with his or her other thumb. The physician then applies a bit of external rotation to the arm when it is fully flexed to 90 degrees, and the physician uses the thumb of his or her other hand to push the patient's humeral head into the glenoid fossa. If one uses the flexed elbow approach to this manoeuvre, the patient appears to be scratching the back of his or her head.

#### Step 1

The physician firmly places his or her hand on the affected shoulder and stabilizes the humeral head with his or her thumb so it does not move inferiorly when the arm is abducted (Fig. 15).

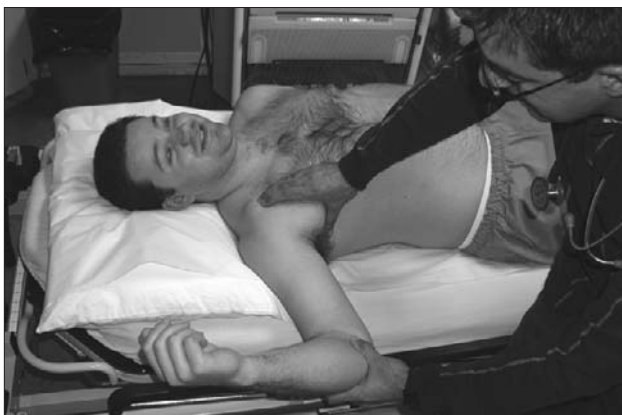

Fig. 15. The physician stabilizes the humeral head as part of the Milch method.

#### Step 2

The physician slowly brings the arm to full abduction. The traction on the arm is increased while the physician pushes up with his or her thumb to replace the humeral head into the glenoid fossa (Fig. 16).

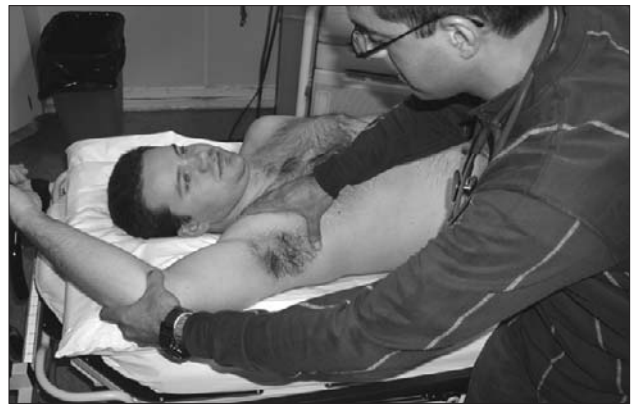

Fig. 16. In the Milch method, the physician abducts the patient's arm.

#### SPASO METHOD

This method is similar to the Milch method except that the end position of the humerus is not full abduction (the overhead-baseball-throwing position), but rather full flexion at 90 degrees.<sup>4</sup>

Essentially, the supine patient is pointing at the ceiling. The physician assists in slowly raising the arm into this position and with gently maintained traction at the patient's wrist, externally rotates the arm. Once at full flexion, wait several minutes maintaining traction. This is all that may be required. Additional assistance in relocating the humeral head can be obtained with direct pressure by finger pressure in the axilla.

#### Step 1

The physician grasps the patient's wrist and with gentle traction, slowly raises the arm to 90 degrees (Fig. 17).

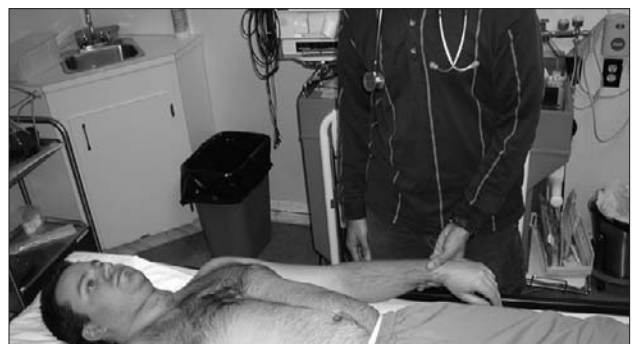

Fig. 17. Initial position of the Spaso method. The physician grasps the patient's wrist.

## Step 2

Once flexed at 90 degrees, the physician externally rotates the arm, maintaining traction (Fig. 18). This may need to be held for several minutes until reduction is achieved. If the patient is painfully raising his or her shoulder off the bed, more analgesia is needed.

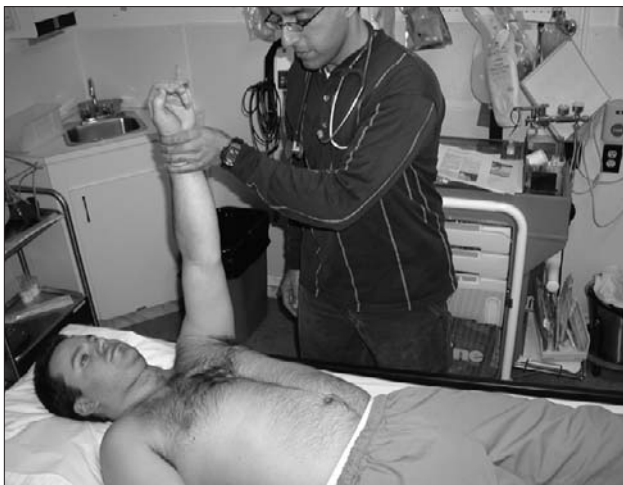

Fig. 18. The full extension of the Spaso method with the patient's arm externally rotated and pointing toward the ceiling.

The humeral head may need help into position with some posterior pressure from the other hand (Fig. 19).

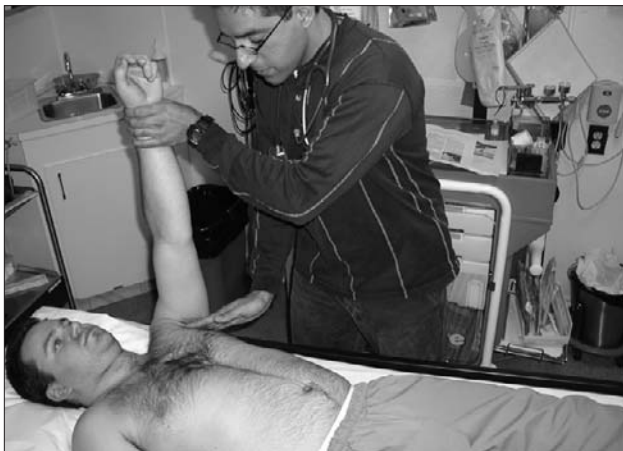

Fig. 19. The Spaso method with the physician applying pressure to the humeral head.

## SELF-REDUCTION IN THE BACK COUNTRY

Canoeists often know all about this method or have had to figure it out themselves. The patient sits against a tree and locks his or her fingers together around his or her bent knees. While he or she sits

there gnomelike, the shoulders are shrugged and the knees are pulled into the chest to accomplish the reduction.

## ANALGESIA

As with most procedures, the clinician must be confident that the patient can be safely monitored and that airway capabilities and monitoring equipment are present and functioning. There are several approaches to analgesia and sedation for reducing shoulders. The physician must be very familiar with his or her choice of medication. Intravenous access is often required. The first and simplest method is injection of 10–20 mL of 1% xylocaine into the dislocated joint. Pain relief is achieved in 5–10 minutes.<sup>16</sup>

I prefer a single agent that is quickly and easily reversible with Narcan. Demerol in 50 mg aliquots until the patient is sedated but rousable is my drug of choice for the traction counter-traction reduction method. Fentanyl is an excellent alternative. Once the successful procedure is completed, the Narcan, already drawn up, is administered to the patient to lessen the need for intense monitoring.

Many clinicians prefer to add medazolam to their narcotic of choice, with excellent results. Some services use ketamine or propofol. All of these are sound choices as long as the practitioner is familiar with the drug and can handle any predictable complications. No one method is superior as long as the patient is safely medicated. If the patient moans and squirms against traction, their sedation is not deep enough. I do not begin traction on the affected limb until the patient is not responding to verbal stimulus.

Gentler reduction methods can be attempted in the right patient, with a calming presence and very gradual joint manipulation.

## POSTREDUCTION CARE

First-time dislocations should be treated with a sling for 4–6 weeks, with the sling initially pinned to the shirt or bandaged to the chest wall to eliminate external rotation. People with repeat dislocations receive less benefit from prolonged immobilization, and can mobilize sooner as long as overhead movements and external rotations are avoided.

Four months without doing sports that require overhead activity is a common recommendation. The evidence is scant for these recommendations, but many researchers<sup>19</sup> agree that the younger, first-time dislocating patient likely receives the most benefit from a sling and avoidance of external rotation.

## REFERENCES

1. Mattick A, Wyatt JP. From Hippocrates to the Eskimo—a history of techniques used to reduce anterior dislocation of the shoulder. *J R Coll Surg Edinb* 2000;45:312-6.
2. Kroner K, Lind T, Jensen J. The epidemiology of shoulder dislocations. *Arch Orthop Trauma Surg* 1989;108:288-90.
3. Baykal B, Sener S, Turkan H. Scapular manipulation technique for reduction of traumatic anterior shoulder dislocations: experiences of an academic emergency department. *Emerg Med J* 2005;22:336-8.
4. Yuen MC, Yap PG, Chan YT, et al. An easy method to reduce anterior shoulder dislocation: the Spaso technique. *Emerg Med J* 2001;18:370-2.
5. Sagarin MJ. Best of both (BOB) maneuver for rapid reduction of anterior shoulder dislocation. *J Emerg Med* 2005;29:313-6.
6. Chitgopkar SD, Khan M. Painless reduction of anterior shoulder dislocation by Kocher's method. *Injury* 2005;36:1182-4.
7. Guha AR, Jago ER. Irreducible acute anterior shoulder dislocation. *Int J Clin Pract* 2004;58:1184-6.
8. Cunningham NJ. Techniques for reduction of anteroinferior shoulder dislocation. *Emerg Med Australas* 2005;17:463-71.
9. Hazmy CH, Parwathi P. The epidemiology of shoulder dislocation in a state-hospital: a review of 106 cases. *Med J Malaysia* 2005;60:17-21.
10. Cluett J. *Shoulder dislocation. Your guide to orthopedics*. Available: <http://orthopedics.about.com/cs/shouldersurgery/a/dislocation.htm> (accessed 2007 Feb 12).
11. Robinson CM, Aderinto J. Posterior shoulder dislocations and fracture dislocations. *J Bone Joint Surg Am* 2005;87:639-50.
12. McRae R. *Practical fracture treatment*. 2nd ed. New York (NY): Churchill Livingstone; 1889. p 88-92.
13. Yeap JS, Lee DJ, Fazir M, et al. Nerve injuries in anterior shoulder dislocations. *Med J Malaysia* 2004;59:450-4.
14. The Orthopedic Research Institute. *All about shoulder dislocation*. Available: [www.ori.org.au/bonejoint/shoulder/reduction.htm](http://www.ori.org.au/bonejoint/shoulder/reduction.htm) (accessed 2007 Feb 12).
15. Regauer VM, Tischer T, Kanz KG, et al. Mutschler. Schonende reposition bei ventraler schulterluxation. *MMW-Fortschr Med* 2005;33-34:729-32.
16. Welsh S, Veenstra M. *Shoulder dislocations*. Available: [www.emedicine.com/orthoped/topic440.htm](http://www.emedicine.com/orthoped/topic440.htm) (accessed 2007 Feb 15).
17. Schubert H. Emergency case: reducing anterior shoulder dislocation. *Can Fam Physician* 2002;48:469-72.
18. Leidelmeyer R. Reduced! A shoulder, subtly and painlessly. *Emerg Med* 1977;9:233-4.
19. Handoll H, Hanchard N, Goodchild L, et al. Conservative management following closed reduction of traumatic anterior dislocation of the shoulder. *Cochrane Database Syst Rev* 2002 Jan 25(1): CD004962.

## DIRECTIVES AUX AUTEURS

Le *Journal canadien de la médecine rurale (JCMR)* est un trimestriel critiqué par les pairs disponible sur papier et sur Internet. Le *JCMR* vise à promouvoir la recherche sur les questions de santé rurale, à promouvoir la santé des communautés rurales (y compris les communautés autochtones), à appuyer et informer les praticiens en milieu rural, à offrir une tribune de débat et de discussion sur la médecine rurale, ainsi qu'à fournir de l'information clinique pratique aux praticiens en milieu rural et à agir sur la politique de santé rurale en publiant des articles qui éclairent les décideurs.

On étudiera la possibilité de publier des documents sur ces questions.

**Articles originaux :** études de recherche, rapports de cas et analyses critiques d'écrits en médecine rurale. **Commentaires :** éditoriaux, analyses régionales, articles d'opinion. **Articles cliniques :** articles pratiques portant sur la pratique en milieu rural. On encourage la présentation d'illustrations et de photos. **Détente :** pot-pourri de documents d'intérêt général pour les médecins ruraux (p. ex., voyages, réflexions sur la vie rurale, dissertations). **Couverture :** Œuvre d'art à thème rural.

**Présentation des manuscrits :** Veuillez envoyer trois copies papier du manuscrit à l'adresse suivante : Rédacteur en chef, *JCMR*, CP 1086, Shawville (Qué.) J0X 2Y0; 819 647-2972; télécopieur : 819 647-9972; présentez également une version électronique à [cjrm@lino.com](mailto:cjrm@lino.com). Il faut joindre une lettre d'accompagnement indiquant que le texte n'a pas été publié ni

soumis pour publication ailleurs. Les copies papier du manuscrit doivent être dactylographiées à double interligne, comporter une page titre distincte, un résumé d'au plus 200 mots, suivi du texte, des références complètes et des tableaux (chaque tableau sur une page distincte).

«**Exigences uniformes pour les manuscrits présentés aux revues biomédicales**» : voir [www.cmaj.ca/authors/policies.shtml](http://www.cmaj.ca/authors/policies.shtml)

**Permissions écrites :** Il faut produire une autorisation écrite des personnes concernées pour utiliser des documents déjà publiés ou des illustrations identifiant des sujets humains, ainsi que de toute personne mentionnée dans les remerciements ou citée comme source d'une communication personnelle.

**Illustrations et figures électroniques :** Les illustrations doivent être sous forme de clichés de bonne qualité, non montés, sur papier luisant d'au plus 8 sur 10 po (20,3 × 25,4 cm). Les figures présentées sur support électronique doivent être conformes aux caractéristiques techniques décrites à [www.amc.ca/cjrm](http://www.amc.ca/cjrm) (cliquez sur «Directives aux auteurs»).

**Références :** Veuillez vous assurer que les références des documents électroniques ne sont pas préparées à l'aide des fonctions notes en fin de texte ou notes en pied de page des logiciels.

**Manuscrits acceptés :** Les auteurs devront présenter la version la plus récente du manuscrit par courriel ou sur disquette. Veuillez indiquer le logiciel utilisé.