



# THE PRACTITIONER LE PRATICIEN

## The management of the occasional trigger finger

Ian P. Sempowski, MD,  
CCFP (EM)

Assistant Professor, Department of Family Medicine,  
Queen's University,  
Kingston, Ont.

Correspondence to:  
Dr. Ian P. Sempowski,  
Haynes Hall Family Health  
Team, 115 Clarence St.,  
Kingston ON K7L 5N6;  
sempowsk@post.queensu.ca

This article has been peer  
reviewed.

### INTRODUCTION

Patients will frequently see their family physician with an “occasional trigger finger,” or a finger or thumb that gets intermittently stuck in a flexed position. By attempting to extend the digit, it will often suddenly pop out to length. In some cases, the trigger finger is painful. Trigger finger usually occurs in the third or fourth digits, but it can occur in the thumb. Excessive gripping, as with a power tool or musical instrument, can increase the risk. Usual age of onset is in the 50s and 60s. Women are at higher risk, as are those with conditions such as rheumatoid arthritis (RA), diabetes, hypothyroidism and gout.<sup>1</sup>

It is believed that recurrent tenosynovitis will lead to narrowing of the synovial sheath below the A1 pulley, as noted in Figure 1. In some cases, the tendon

enlarges and forms a nodule distal to the pulley. As the finger is flexed, the thickened section of tendon becomes trapped proximal to the narrowing at the level of the pulley. With persistence or manual extension, using the other hand, the nodule pops through the stenotic section of tendon sheath.<sup>2</sup> In severe cases, however, the finger can become stuck in the flexed position, resulting in a flexion contracture.

On examination there is often tenderness to palpation in the area of the A1 pulley just proximal to the metacarpal-phalangeal (MCP) joint. There may also be a palpable nodule distal to this area, and this nodule will generally move with finger flexion and extension.

The differential diagnosis of trigger finger includes other conditions such as Dupuytren's contracture, a thickening of the palmar fascia, which over time pulls the finger into flexion but does not cause triggering. Additionally, abnormalities of the MCP joint such as osteophytes, loose bodies or chronic subluxation can lead to triggering.

### CONSERVATIVE TREATMENT

In many cases, rest and avoidance of gripping activities will alleviate symptoms. Nonsteroidal anti-inflammatory drugs can be used to reduce swelling and pain. Splinting of the distal interphalangeal (DIP) joint with the proximal interphalangeal (PIP) joint left mobile can also be used.<sup>3,4</sup> In this technique, a sandwich composed of 2 layers of Coban wrap (Emergency Medical Products Inc.) enclosing a paper clip is placed on the dorsal aspect of the DIP.

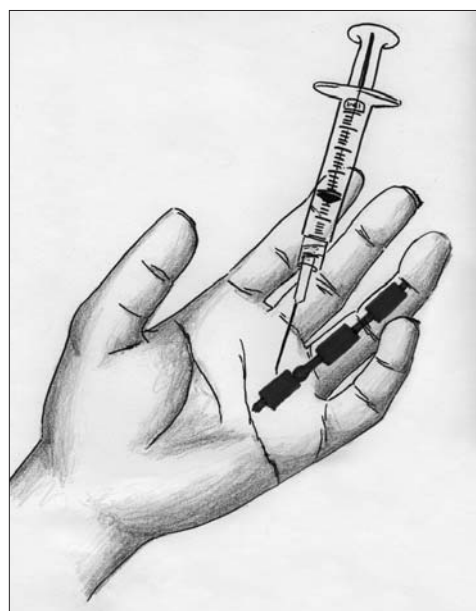

Fig. 1. Illustration of a trigger finger showing the narrowing of the synovial sheath below the A1 pulley.

## CORTICOSTEROID INJECTION

Patients with symptomatic trigger fingers who do not respond to conservative therapy are candidates for an injection of corticosteroid into the tendon sheath. In 1990, Newport and colleagues<sup>5</sup> published a retrospective study of 235 patients with 338 trigger fingers. Seventy-seven percent of all fingers showed resolution or improvement — 49% after a single injection, 23% after 2 injections and 5% after 3 injections. Lambert and coauthors<sup>6</sup> subsequently published a prospective study that showed a 60% response to steroid injection versus 16% for placebo ( $p < 0.05$ ). Anderson and Kaye<sup>7</sup> confirmed a similar response rate of 61% to an initial injection, but they also showed that with recurrent injections only 12% of cases were treatment resistant. Patients with RA or diabetes are considered to be at higher risk of treatment failure.<sup>1</sup> Nimigan and coworkers<sup>8</sup> reported a 32% success rate in patients with diabetes, compared with 57% in those without.

### THE PROCEDURE

1. The equipment required to perform an injection into the tendon sheath is outlined in Box 1.
2. Informed consent should be obtained following a discussion of the risks and benefits. The success rate of an initial injection can be summarized as being 30% in those with diabetes and 60% in those without. Complications of this procedure include localized infection, bruising and stiffness at the injection site. Localized atrophy of subcutaneous tissue may occur but has not been found to be a significant impairment. Additionally, patients with diabetes may experience a transient rise in blood glucose readings.<sup>8,9</sup> Tendon rupture is a theoretical risk, especially in RA patients, but studies have not shown this to be a common complication.<sup>10,11</sup>
3. The area of the affected digit is prepped with

#### Box 1. Equipment required for a corticosteroid injection of a trigger finger

- Sterile dressing tray
- Sterile gloves
- Chlorhexidine
- 4 × 4 gauze
- 3 mL syringe
- 27 G 5/8 inch needle
- Corticosteroid — methylprednisolone (Depot Medrol) 40 mg/mL or triamcinolone (Kenalog) 40 mg/mL
- Adhesive bandage

chlorhexidine and draped in a sterile manner.

4. The area of the pulley is palpated just proximal to the MCP joint. As shown in Figure 2, the proximal border of the A1 pulley is proximal to the interdigital crease by approximately the same distance (A) as measured between the proximal digital crease and the interphalangeal crease. The average length of the pulley is 1.2 cm, and using these landmarks, a pen can be used to mark out the location of the pulley.<sup>12</sup>
5. The corticosteroid used in most studies was either methylprednisolone (Depot Medrol) 40 mg (1 mL) or triamcinolone (Kenalog) 20 mg (0.5 mL). The steroid is drawn up in a 3-mL syringe and diluted with 1% lidocaine plain (no epinephrine) to a total volume of 2–3 mL.<sup>6</sup> The syringe, with a 25- or 27-G 5/8-inch needle attached, is inserted obliquely at a 45° angle over the tendon sheath either proximal, over or distal to the A1 pulley.
6. The needle is then advanced until it meets the resistance of the tendon.
7. The patient is asked to flex and extend the finger gently. If the needle is in fact embedded in the tendon, the needle will move with the finger. If the needle is gently “kissing” the tendon a sharp grating palpable and audible crepitus will be encountered with finger movement and there will be no movement of the needle.
8. This is the best time to gently inject the medication as this grating crepitus will give you a good chance of injecting it into the sheath but not into the tendon sheath. This very helpful sign is caused by the presence of transverse bands along the surface of the tendon. Studies have in fact




Fig. 2. Surface landmarks and the location of the A1 pulley. The proximal border of the A1 pulley is proximal to the interdigital crease by approximately the same distance (A) as measured between the proximal digital crease and the interphalangeal crease.

shown that corticosteroids will be efficacious even if injected alongside the sheath, but ideally the majority should be injected into the sheath.

9. The needle is then withdrawn and a dressing is applied.
10. Over 5 minutes, the distal finger will become frozen from diffusion down the sheath despite the fact that the local anesthetic was not injected laterally near the interdigital nerves. This confirms correct location of the injected medication. The patient can expect an improvement within 2 weeks. Partial- or nonresponders can be considered for a second or third injection.

### **SURGICAL THERAPY**

In patients who do not respond to conservative therapy combined with corticosteroid injections, surgical release may be indicated. Some authors recommend repeated injections, while others such as Benson and Ptaszek<sup>15</sup> have postulated that it may be more cost-effective in the long term to offer surgery after 1 failed injection. A hand surgeon can release the A1 pulley either percutaneously or following an open surgical procedure.

### **CONCLUSION**

Patients with trigger finger can be initially managed with conservative measures, including modification of activities. If this fails, approximately 60% of patients will respond to a corticosteroid injection of the tendon sheath. Additional patients will respond to a second or third injection. Patients with diabetes have a lower response rate of approximately 30%. The presence of a palpable grating as the needle touches the tendon in combination with a lack of association between the movement of the

finger and the needle confirms proper needle placement. Corticosteroid injection of the tendon sheath can be performed safely and effectively in a family physician's office.

**Acknowledgements:** Thank you to Dr. Nadia Alam for her assistance with the illustrations and in editing the manuscript.

**Competing interests:** None declared.

### **REFERENCES**

1. Griggs SM, Weiss AP, Lane LB, et al. Treatment of trigger finger in patients with diabetes mellitus. *J Hand Surg [Am]* 1995;20:787-9.
2. Akhtar S, Burke FD. Study to outline the efficacy and illustrate techniques for steroid injection for trigger finger and thumb. *Postgrad Med J* 2006;82:763-6.
3. Patel MR, Bassini L. Trigger fingers and thumb: when to splint, inject, or operate. *J Hand Surg [Am]* 1992;17:110-3.
4. Rhoades CE, Gelberman RH, Manjarris JF. Stenosing tenosynovitis of the fingers and thumb: results of a prospective trial of steroid injection and splinting. *Clin Orthop Relat Res* 1984;190:236-8.
5. Newport ML, Lane LB, Stuchin SA. Treatment of trigger finger by steroid injection. *J Hand Surg [Am]* 1990;15:748-50.
6. Lambert MA, Morton RJ, Sloan JP. Controlled study of the use of local steroid injection in the treatment of trigger finger and thumb. *J Hand Surg [Br]* 1992;17:69-70.
7. Anderson B, Kaye S. Treatment of flexor tenosynovitis of the hand ('trigger finger') with corticosteroids. A prospective study of the response to local injection. *Arch Intern Med* 1991;151:153-6.
8. Nimigan AS, Ross DC, Gan DC, et al. Steroid injections in the management of trigger fingers. *Am J Phys Med Rehabil* 2006;85:36-43.
9. Wang AA, Hutchison DT. The effect of corticosteroid injection for trigger finger on blood glucose level in diabetic patients. *J Hand Surg* 2006;31:979-81.
10. Paavola M, Kannus P, Jarvinen TA, et al. Treatment of tendon disorders. Is there a role for corticosteroid injection? *Foot Ankle Clin* 2002; 7:501-13.
11. Karpman RR, McComb JE, Volz RG. Tendon rupture following local corticosteroid injection: report of four cases. *Postgrad Med J* 1980;68: 169-74.
12. Akhtar S, Burke FD. Study to outline the efficacy and illustrate techniques for steroid injection for trigger finger and thumb. *Postgrad Med J* 2006;82:763-6.
13. Benson LS, Ptaszek AJ. Injection versus surgery in the treatment of trigger finger. *J Hand Surg [Am]* 1997;22:138-44.

## **Read the Rural News**

A bonus to all RuralMed listserv subscribers is the *Rural News*, an email newsletter about rural medicine.

Subscription to RuralMed is by request. Send an email to: [admin@srpc.ca](mailto:admin@srpc.ca) or access the subscription form at [www.srpc.ca](http://www.srpc.ca)