



## Country cardiograms case 34

Charles Helm, MD,  
CCFP  
Tumbler Ridge, BC

Correspondence to:  
Dr. Charles Helm,  
Box 1690, Tumbler Ridge  
BC V0C 2W0;  
orbhel@pris.bc.ca

This article has been peer  
reviewed.

**A** 43-year-old man presents to the emergency department of a rural British Columbia hospital with a 3-hour history of chest pain. Soon after his arrival he develops ventricular fibrillation and is promptly defibrillated.

His vital signs return to normal with a palpable radial pulse. An electrocardiogram is obtained (Fig. 1). What is your diagnosis?

**For the answer, see page 126.**

**Competing interests:** None declared.

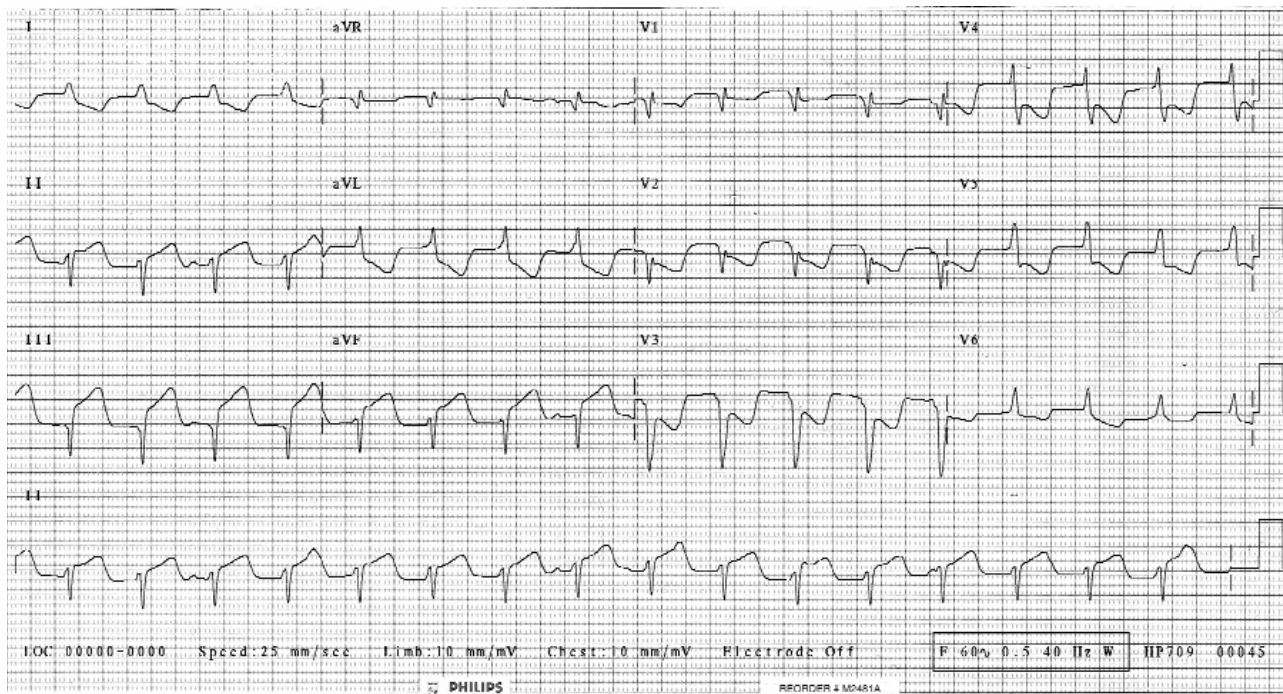


Fig. 1. Electrocardiogram of a 43-year-old man who presented to the emergency department with a 3-hour history of chest pain.

“Country cardiograms” is a regular feature of *CJRM*. We present an electrocardiogram and discuss the case in a rural context. Please submit cases to Suzanne Kingsmill, *CJRM*, P.O. Box 4, Station R, Toronto ON M4G 3Z3.