

## Country cardiograms case 41

*Brent M. McGrath, MD, MSc, PhD*  
Department of Medicine,  
Faculty of Medicine,  
Dalhousie University,  
Halifax, NS

*Jeff Moore, MD, FRCPC*  
Department of Medicine,  
Dr. Everett Chalmers Regional  
Hospital, Fredericton, NB

Correspondence to:  
*Dr. Brent M. McGrath,*  
Department of Medical  
Education 5DS, Saint John  
Regional Hospital,  
400 University Ave.,  
PO Box 2100, Saint John NB  
E2L 4L2; [brent.mcgrath@dal.ca](mailto:brent.mcgrath@dal.ca)

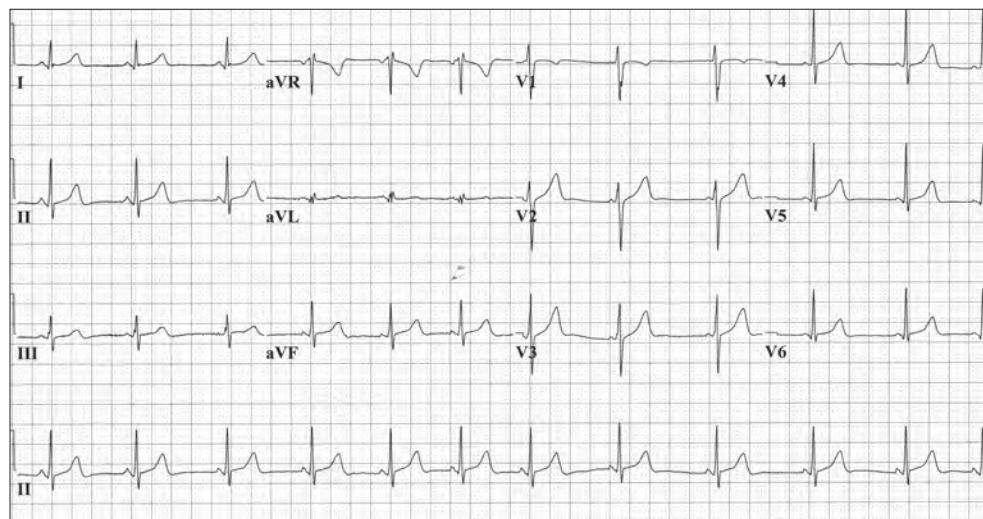
*This article has been peer reviewed.*

**A** 16-year-old girl who is otherwise healthy reports several episodes of palpitations. She describes a heart rate that is “too fast to count” as well as occasional associated shortness of breath and nausea. The episodes occurred during both rest and activity and ranged from 3 to 10 minutes in duration. Physical examination is normal, and the patient reports taking only oral contraceptive medication (not new) and denies abusing drugs. Results

of routine laboratory investigations are normal, including tests of thyroid function. A 24-hour Holter monitor fails to record any episodes. The patient did not have an electrocardiogram (ECG) during any of the episodes; however, a routine ECG has been obtained (Fig. 1). What is the ECG diagnosis?

**For the answer, see page 141.**

**Competing interests:** None declared.



**Fig. 1.** Routine electrocardiogram of a 16-year-old girl who reports several self-limited episodes of a racing heart rate.

“Country cardiograms” is a regular feature of *CJRM*. We present an electrocardiogram and discuss the case in a rural context. Please submit cases to Suzanne Kingsmill, *CJRM*, 45 Overlea Blvd., P.O. Box 22015, Toronto ON M4H 1N9; [cjrm@cjrm.net](mailto:cjrm@cjrm.net).