

Country cardiograms case 50

*Charles Helm, MD,
 CCFP
 Tumbler Ridge, BC*

*Correspondence to: Charles
 Helm; helm.c.w@gmail.com*

*This article has been peer
 reviewed.*

An 84-year-old man is brought to the emergency department in a remote BC community with a history of episodes of dizziness for the preceding several hours. A week previously he had been in a car crash in which he lost consciousness while driving. His previous electrocardiograms have shown first-degree

atrioventricular block and right bundle branch block. The following electrocardiogram is recorded (Fig. 1). What is your interpretation, and what needs to be done?

For the answer, see page 77.

Competing interests: None declared.

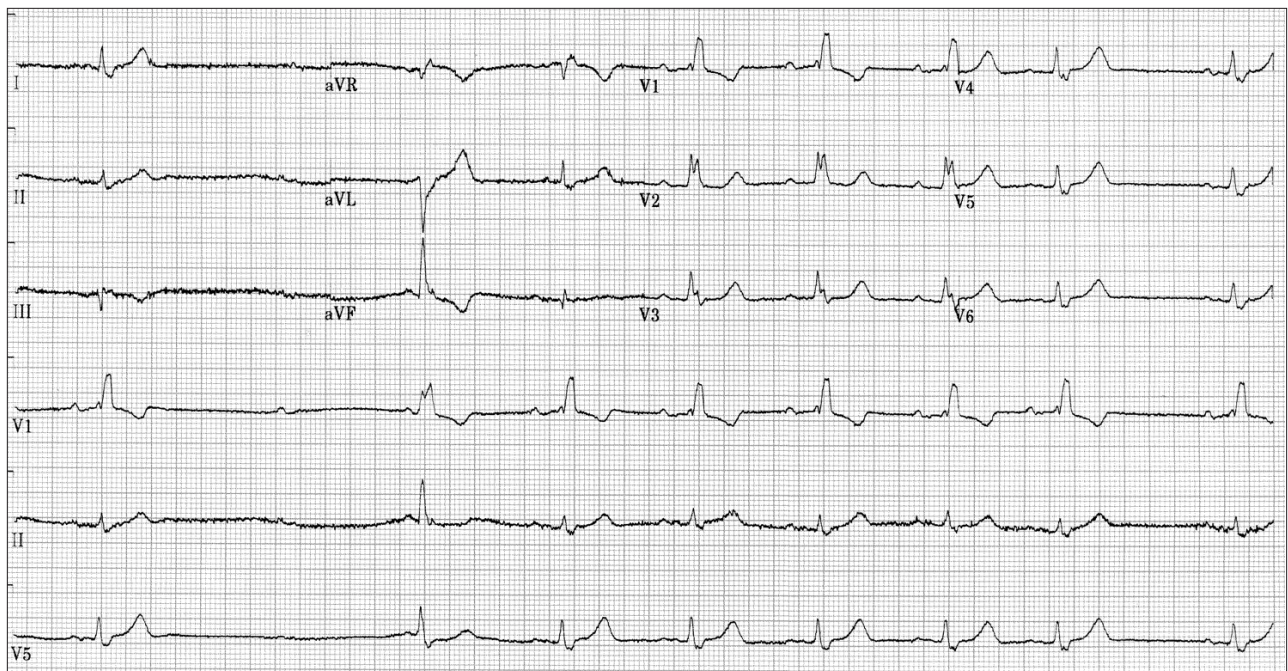


Fig. 1. Electrocardiogram of an 84-year-old man with episodes of dizziness.