Canadian Journal of Rural Medicine
CJRM CMR
Journal canadien de la médecine rurale

The occasional ED ultrasound: abdominal aorta

Kyle Sue, MD
Discipline of Family Medicine, Faculty of Medicine, Memorial University of Newfoundland, St. John's, NL; Canadian Emergency Ultrasound Society (CEUS) Independent Practitioner

Correspondence to: Kyle Sue; ksue@ualberta.ca

This article has been peer reviewed.

INTRODUCTION

As a rural practitioner, one is often faced with situations of diagnostic uncertainty. Making the wrong decision could be disruptive and costly, or could lead to substantial morbidity and even mortality. Being comfortable with point-of-care ultrasonography as an adjunct to physical examination can therefore be practice-changing and life-saving. The purpose of point-of-care ultrasonography in an emergency setting is to allow the physician to quickly rule in or rule out suspected life-threatening conditions, such as an abdominal aortic aneurysm (AAA) as the cause of a patient's abdominal pain.[1] As an example, if a patient presents to a rural emergency department (ED) with sudden, severe abdominal pain, could the cause of it be a ruptured AAA? The patient may not necessarily have hypotension if the rupture is contained.[2] Conversely, if a patient presents to a rural ED with consistent abdominal discomfort that has been gradually worsening over the past month, could the discomfort be secondary to an AAA?[3] Your primary goal for the occasional ultrasound in a rural ED is to assess it safely. The key to safety is not the ability to call a scan positive or negative, but knowing when to call it inconclusive. If you are not sure, continue management as if you had never done the scan at all.[4]

EQUIPMENT

- Any ultrasound machine
- Low frequency (2–5 MHz) curvilinear probe (Fig. 1)
- Ultrasound gel or water-based lubricant

IMAGE GENERATION AND INTERPRETATION

Locate the spine

Identification of the aorta is easiest to do by first locating the spine. The spine appears as a bright, hyperechoic (white) curvilinear structure in the far field (bottom of screen). Because bone



Fig. 1. Low frequency (2–5 MHz) curvilinear probe.

does not conduct ultrasound waves, the spine casts an acoustic shadow (dark lines on each side) posteriorly, called the spine shadow.

Locate the aorta

The aorta is typically found just anterior and slightly right of the spine on the screen (left on the patient).

To differentiate the aorta from the inferior vena cava (IVC), consider the following:[3]

- The aorta is noncompressible. If you push the probe into the patient and the circle flattens and the black fluid disappears, that circle is the IVC.
- The aortic wall is thicker than the IVC wall, so it will show up as being brighter (more echogenic).
- The aorta has no respiratory variability. The IVC collapses slightly with inspiration owing to negative intrathoracic pressure.

You might not see both vessels, so you will need to use the above criteria to definitively identify the aorta. Not all aortas are on the patient's left (right side of screen). Do not identify the aorta simply based on it being large and pulsating — the aorta's pulsations can make the nearby IVC pulsate as well!

THE PROCEDURE

Ensure you have a good amount of ultrasound gel on the probe. Start with the probe held transverse with the probe marker to the patient's right, 90 degrees to the skin, at the xiphoid process (Fig. 2). While keeping the probe 90 degrees to the skin in transverse orientation, slowly bring the probe caudally with the aorta centred on the screen. When you reach the approximate location of the umbilicus, the aorta bifurcates into the right and left iliac arteries.[4]

To have a conclusively negative scan, you must be able to visualize continuously every segment of the abdominal aorta from the diaphragm to the bifurcation.[3] However, you do not need to see the entire aorta to call a scan positive if you can visualize any segment that is aneurysmal.[4] Do not worry about other vessels you see branching off the aorta (e.g., the celiac axis, the superior mesenteric artery), which are often difficult to visualize. Just be able to document how far between the diaphragm and the bifurcation (e.g., first third, second third, final third) the aneurysm is located.

Caveats

- Bowel gas can get in the way of visualizing the aorta in its entirety.[5]
- Ultrasound cannot be used by itself to identify aneurysmal ruptures; most ruptures are retroperitoneal and cannot be seen on a point-of-care ultrasound.[6] However, if the ultrasound is positive for AAA, do a focused assessment with sonography in trauma (FAST) scan to look for free fluid.[3]

Troubleshooting for bowel gas

To get around bowel gas[3,4] try moving the probe medially or laterally. As long as you still visualize the spine and the probe remains 90 degrees to the skin, it is okay to be off-centre. Try using the probe to displace bowel loops with downward pressure. If the assessment is not urgent, you could try the scan again later — the bowel gas may have moved by then. You can also tilt the probe cephalad or caudad so that it is no longer 90 degrees to the skin, but keep in mind that your diameter measurements will no longer be accurate when you are slicing the vessel on an angle. If you see the aorta but it is hard to follow, decrease the depth and increase the gain (make the vessel walls brighter).

To measure

Each machine is different, but generally you will need to freeze the image where you want it, and use calipers to measure from one side of the vessel wall to the exact opposite side.

Diagnosis

An aortic diameter of less than 3 cm is normal. A diameter greater than 3 cm is aneurysmal. Abdominal

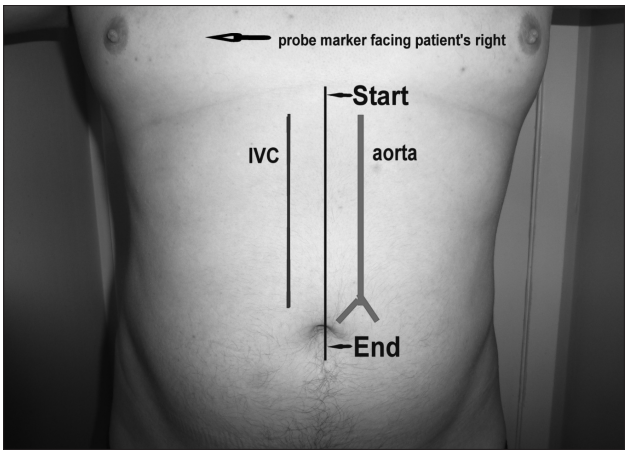

Fig. 2. Landmarks for using a point-of-care ultrasound for diagnosis of abdominal aortic aneurysm. Start centrally at the xiphoid process, and move probe caudally toward the umbilicus. IVC = inferior vena cava.

aortic aneurysm can be diagnosed if the aorta is enlarged at any point. (For iliac arteries, a diameter of less than 1.5 cm is normal.)[3,4]

Measurements are from the echogenic outer wall to the echogenic outer wall on the opposite side. Do not simply measure the size of the lumen! There could be a thrombus that makes the lumen much narrower than the aortic diameter.[3,4]

THREE CASE HISTORIES

Case A

A 25-year-old man presents to your rural ED with sudden-onset, severe central abdominal pain. The patient is afebrile, with no nausea, vomiting or diarrhea. He is diaphoretic, his blood pressure is 150/90 mm Hg and his heart rate is 102 beats/min. Physical examination of the abdomen reveals diffuse tenderness with no guarding or rebound tenderness. As part of your physical examination, you reach for the ultrasound probe to ensure the cause of his pain is not a ruptured but contained AAA (Fig. 3).

You measure the widest part of the abdominal aorta to be 2.4 cm. Therefore, an AAA is not the cause of this patient's pain.

Case B

A 65-year-old man with Marfan syndrome presents to your rural ED with severe abdominal pain, hypotension, back pain and diminished femoral pulses. You highly suspect an AAA as a cause of his signs and symptoms, and you use the ultrasound probe to confirm (Fig. 4).

You discover an AAA measuring 8 cm in diameter. Therefore, the most likely diagnosis is a ruptured AAA. This patient is hemodynamically unstable and unlikely to survive.[7,8] The diagnosis and prognosis should be discussed with the patient and family members, advance directives reviewed and spiritual care arranged if desired by the patient. Temporary supportive measures should include pain control, likely requiring generous analgesic use. Fluid resuscitation and blood transfusion can be considered[9,10] if a transfer to a tertiary care centre with vascular surgery is planned. However, this is feasible only if the transfer times from your facility are short.[11]

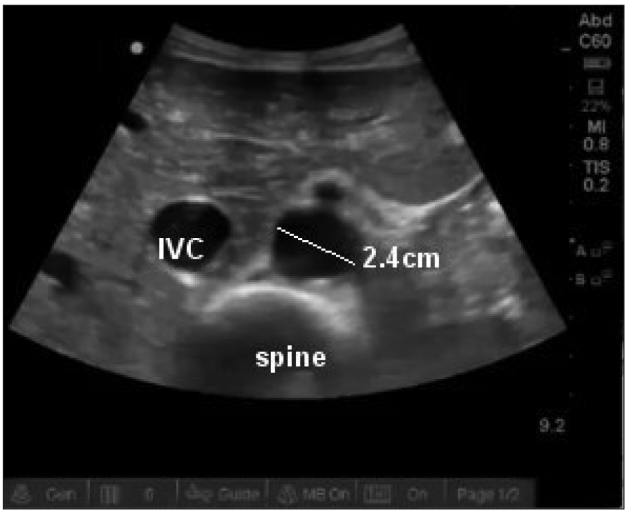

Fig. 3. Ultrasound showing a normal abdominal aorta measuring 2.4 cm. Note the thicker wall of the aorta versus the inferior vena cava (IVC). Unfortunately, in a still image, we cannot use the criteria of lack of respiratory variability and noncompressibility to differentiate the aorta from the IVC.

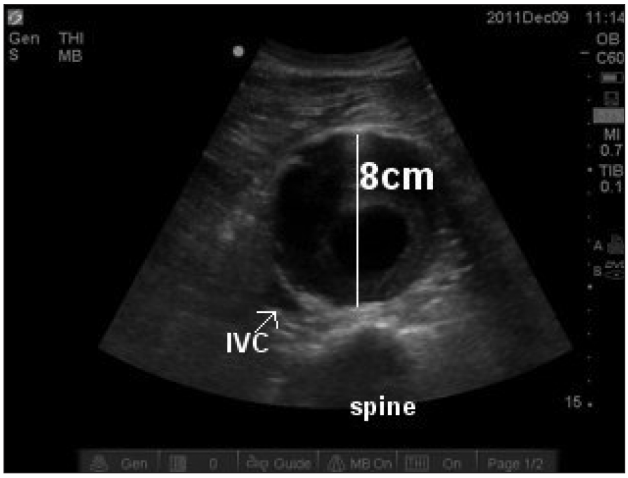

Fig. 4. Ultrasound showing an abdominal aortic aneurysm measuring 8 cm, the widest diameter measured wall to wall. IVC = inferior vena cava.

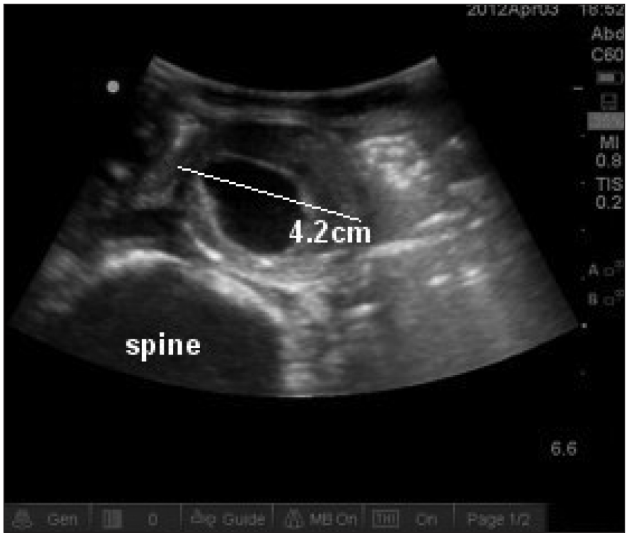

Fig. 5. Ultrasound showing an abdominal aortic aneurysm measuring 4.2 cm, the widest diameter measured from wall to wall. Note the lumen is much smaller than the aortic diameter.

Case C

A 42-year-old woman presents to your rural ED with severe abdominal pain in the right upper quadrant, unexplained hypotension and a temperature of 39.8°C. You suspect septic cholecystitis rather than a ruptured AAA. However, you happen to already have the ultrasound probe by the bedside and decide that spending a few seconds to do a quick abdominal scan will do no harm (Fig. 5).

As a result, you discover that this patient indeed has an AAA measuring 4.2 cm. However, given the fever, this should be low on your list of differential diagnoses for this patient's signs and symptoms. In this situation, it is important to notify the patient of your incidental discovery and ensure appropriate follow-up for the AAA in the future.

Acknowledgements: Thank you to Dr. Andrew Smith, Clinical Assistant Professor of Emergency Medicine, Memorial University of Newfoundland, for providing the ultrasound images. He is also a Canadian Emergency Ultrasound Society (CEUS) Master Instructor and emergency physician at the Health Sciences Centre and St. Clare's Mercy Hospital in St. John's, NL. Thank you also to Dr. Richard McCrea of Saskatchewan for generously exposing his abdomen for Figure 2.

Competing interests: None declared.

REFERENCES

1. Plummer D, Clinton J, Matthew B. Emergency department ultrasound improves time to diagnosis and survival in ruptured abdominal aortic aneurysm. *Acad Emerg Med* 1998;5:417.
2. Ernst CB. Abdominal aortic aneurysm. *N Engl J Med* 1993;328: 1167-72.
3. Barkin AZ, Rosen CL. Ultrasound detection of abdominal aortic aneurysm. *Emerg Med Clin North Am* 2004;22:675-82.
4. Wiss R, Socransky S. *Point-of-care ultrasound for emergency physicians: "the EDE book"*. The EDE Course; 2012. p. 17–23.
5. Rose WM III, Ernst CB. Abdominal aortic aneurysm. *Compr Ther* 1995;21:339-43.
6. Shuman WP, Hastrup W Jr, Kohler TR, et al. Suspected leaking abdominal aortic aneurysm: use of sonography in the emergency room. *Radiology* 1988;168:117-9.
7. Shiraev T, Condous MG. Incidence and outcomes of ruptured abdominal aortic aneurysms in rural and urban Australia. *ANZ J Surg* 2013;83:838-43.
8. Adam DJ, Mohan IV, Stuart WP, et al. Community and hospital outcome from ruptured abdominal aortic aneurysm within the catchment area of a regional vascular surgical service. *J Vasc Surg* 1999;30:922-8.
9. Kauvar DS, Sarfati MR, Kraiss LW. Increased transfusion of autologous blood but not plasma is associated with improved survival in ruptured abdominal aortic aneurysm. *J Vasc Surg* 2011;54:594.
10. Vun S, Walker SR. Endovascular repair of ruptured abdominal aortic aneurysms in a rural center is both feasible and associated with reduced blood product requirements. *Vascular* 2009;17:303-8.
11. Mell MW, Callcut RA, Bech F, et al. Predictors of emergency department death for patients presenting with ruptured abdominal aortic aneurysms. *J Vasc Surg* 2012;56:651-5.