

## Country cardiograms case 55

Charles Helm, MD,  
CCFP

Tumbler Ridge, BC

Correspondence to: Charles  
Helm; helm.c.w@gmail.com

This article has been peer  
reviewed.

**A** 25-year-old man presents to a rural emergency department reporting profound weakness. He has trouble ambulating and struggles to raise his limbs while supine. He reports generalized muscle discomfort but no severe chest pain. He is not taking any prescription medications.

His blood pressure is 170/110

mm Hg; the rest of his vital signs are normal. As part of his investigations, blood tests are done and an electrocardiogram (ECG) is obtained (Fig. 1).

What is the ECG interpretation, and what is the most likely diagnosis?

**For the answer, see page 146.**

**Competing interests:** None declared.

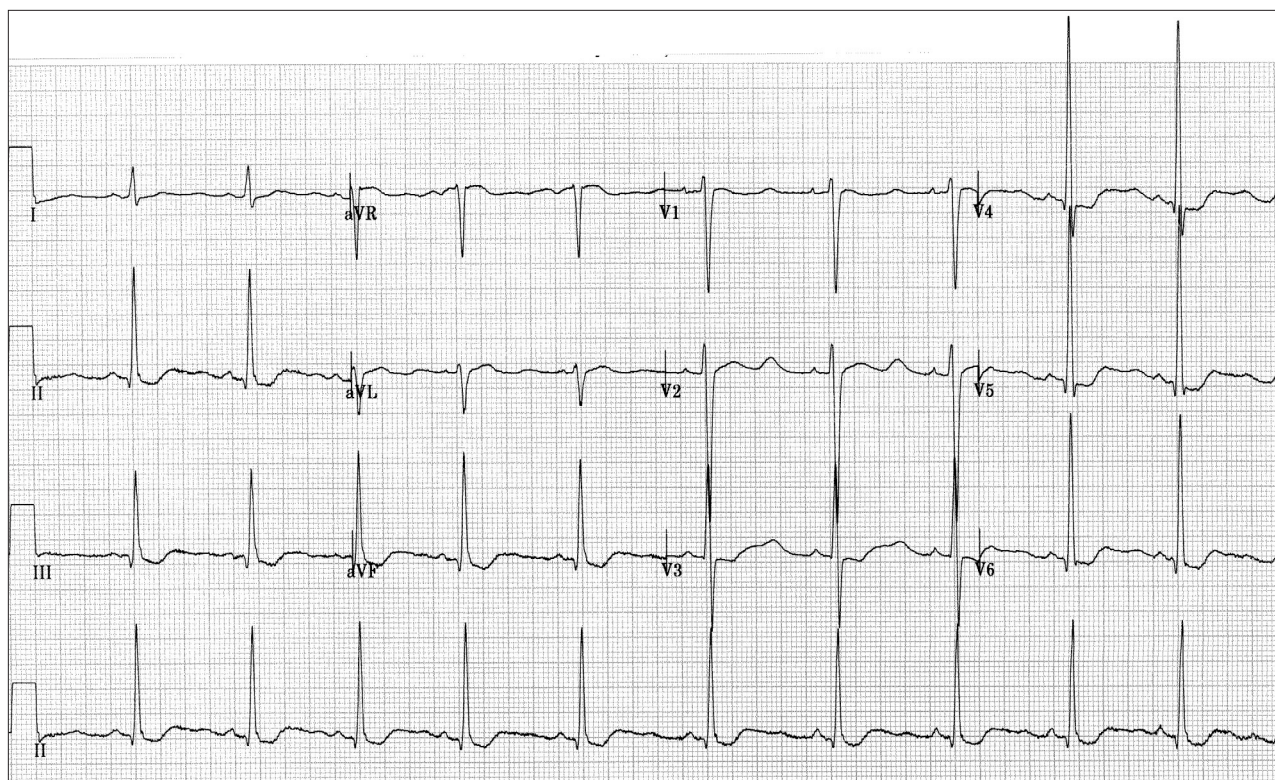


Fig. 1. Electrocardiogram of a 25-year-old man presenting to the emergency department with profound weakness.