

# Point-of-care ultrasonography training for rural family medicine residents — its time has arrived

*Taft Micks, MD*  
Discipline of Family Medicine,  
Faculty of Medicine, Memorial  
University of Newfoundland,  
St. John's, NL

*Andrew Smith, MEng,  
MD, CCFP(EM)*  
Discipline of Emergency  
Medicine and Point of Care  
Ultrasound Education,  
Faculty of Medicine; Faculty  
of Engineering and Applied  
Science, Memorial University  
of Newfoundland, St. John's,  
NL

*Mike Parsons, MD,  
CCFP(EM)*  
*Tony Locke, MD,  
CCFP(EM), FCFP*  
*Peter Rogers, MD,  
CCFP(EM)*  
Disciplines of Emergency  
Medicine and Family  
Medicine, Faculty of  
Medicine, Memorial  
University of Newfoundland,  
St. John's, NL

Correspondence to:  
Taft Micks;  
mickstaft@gmail.com

This article has been peer  
reviewed.

### CASE PRESENTATION

A 53-year-old man presented to our rural emergency department with a 2-day history of progressive, intermittent pain in his right upper quadrant that radiated to his back. This pain was sharp, rated 7/10 on a pain scale and had woken the patient from sleep. There was no nausea, vomiting, diarrhea or change in symptoms with eating. His medical history was remarkable only for a cholecystectomy 6 years earlier. He had quit smoking but had a 40-pack-years history. He consumed 26 oz of alcohol per month. His family history was noncontributory. On physical examination, he had an average build and was in no acute distress. Vital signs were stable except for an initial blood pressure reading of 175/103 mm Hg that decreased to 139/88 mm Hg without treatment. His epigastrium and right upper quadrant were tender to palpation, and there were no signs of acute abdominal pulsation. The pain worsened with flexion and extension of the patient's lumbar spine. Distal pulses were equal and present bilaterally. The physical examination was otherwise unremarkable.

Blood tests revealed a normal complete blood count, and normal amylase, creatinine and liver enzyme levels. Urinalysis and electrocardiography were noncontributory. The patient's pain settled with a single intramuscular dose of ketorolac. Before discharge, the patient was asked if point-of-care ultrasonography could be performed for training purposes by the principal author (T.M.), who was a first-year family medicine resident at the time and had recently completed training in point-of-care ultraso-

nography at Memorial University. The scan revealed a 5.1-cm abdominal aortic aneurysm (AAA) (Fig. 1). Sue<sup>1</sup> provides a detailed explanation on how to perform ultrasonography for suspected AAA.

Emergent computed tomography with contrast confirmed a 5.1-cm AAA; the provisional report suggested either a contained leak or impending rupture (Fig. 2). A vascular surgeon was consulted by telephone, and the patient was airlifted to a tertiary referral centre in St. John's, NL, for further assessment.

### MEMORIAL UNIVERSITY'S POINT-OF-CARE ULTRASONOGRAPHY COURSE

In October 2014, Memorial University's Faculty of Medicine formally integrated point-of-care ultrasonography training into its rural family medicine training program. To the authors' knowledge, this distributed training program is the first of its kind in Canada. Training consisted of online lectures introducing basic skills and concepts, followed by 1.5 days of competency development. Specific skills included focused assessment with sonography for trauma (FAST), early pregnancy assessment, detection of AAA and limited cardiac echocardiography. Competency standards were defined as per the Canadian Emergency Ultrasound Society Independent Practitioner (CEUS IP) guidelines, requiring 50 supervised and determinate scans in each area, followed by written, visual and practical examinations.<sup>2</sup>

At the end of the course, family medicine residents had completed on average 10 to 15 supervised scans before

moving to their rural placements to work on their competency training. A total of 7 rural sites in Newfoundland and Labrador (Clarenville, Gander, Grand Falls–Windsor, Twillingate, Corner Brook, Channel–Port aux Basques and Happy Valley–Goose Bay) have been identified as training sites for competency development, with CEUS IP–certified physicians working in the rural emergency department. Additional efforts are currently underway to enhance these centres and bring additional rural training sites onboard.

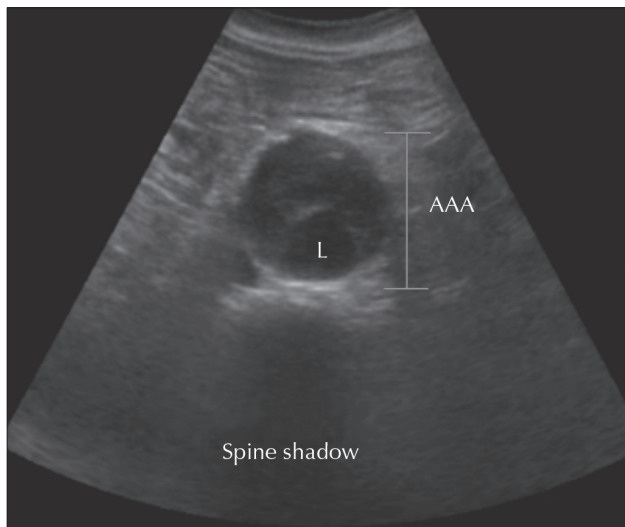


Fig. 1. Ultrasonography image showing the lumen of the abdominal aorta (L) and extent of the abdominal aortic aneurysm (AAA). The spine shadow is the key landmark and represents an artifact produced by the vertebral body.

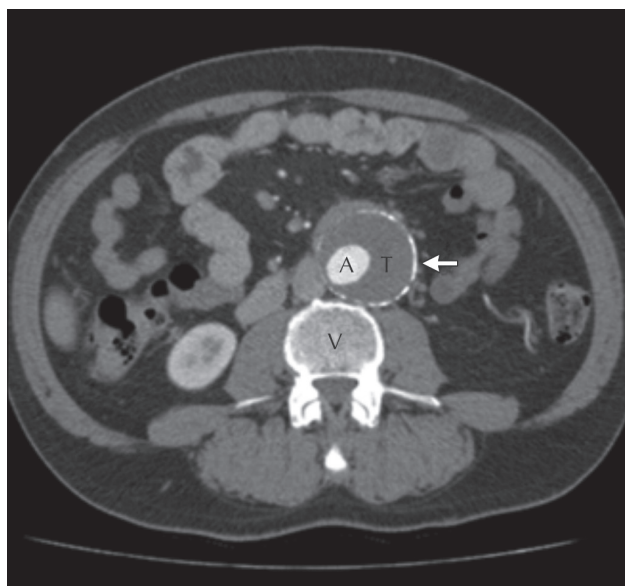

Fig. 2. Transverse view of the abdominal computed tomography scan with contrast showing a 5.1-cm abdominal aortic aneurysm with calcification of the aneurysmal wall (arrow). A circumferential thrombus has formed (T) within the aneurysmal sac adjacent to the abdominal aorta (A). A vertebral body can also be seen (V).

## RESIDENT REFLECTION

This experience has had an immeasurable impact on my medical practice (T.M). I was able to diagnose this man’s potentially life-threatening condition with a bedside examination that took less than a minute to perform. His undiagnosed AAA could have ruptured at any time. This single encounter validated why I received this training and illustrated the potential impact it could have on my clinical decision-making. Since then, I have achieved my CEUS IP certification, completing the 200 required scans in a span of 3 months while on my emergency medicine and obstetrics–gynecology rotations. During my emergency medicine rotation, I was able to apply my ultrasonography skills to patients presenting with trauma, abdominal pain and first-trimester vaginal bleeding. While on my obstetrics–gynecology rotation, I have been able to confirm intrauterine pregnancies in newly pregnant women who had been referred to our service via consultation. Using this technology has helped to solidify my theoretical textbook knowledge with practical, real-time patient anatomy and pathology.

I will definitely be using point-of-care ultrasonography in my future family practice to screen for AAAs, as the Canadian Society for Vascular Surgery advocates a single examination for all men older than 65 years of age and for women with multiple risk factors for vascular disease.<sup>3</sup> I will continue to develop more advanced ultrasonography skills (e.g., detection of cholecystitis or pleural effusions) and apply these skills in the rural emergency department, where obtaining more advanced imaging can be difficult. Had I not received Memorial University’s point-of-care ultrasonography training, I would never have acquired the skills and confidence to use this technology so early in my residency training. In the future, I intend to be a rural instructor in point-of-care ultrasonography and use my skills to teach the next generation of medical students and residents. I strongly encourage other rural family medicine residency programs to offer this training to their residents, so that they may experience the same benefits that I have.

**Competing interests:** None declared.

## REFERENCES

1. Sue K. The occasional ED ultrasound: abdominal aorta. *Can J Rural Med* 2014;19:103-6.
2. Canadian Emergency Ultrasound Society. Core certification. Available: [www.ceus.ca/ceus-certifications/levels-certification/basic-ip-1-certification](http://www.ceus.ca/ceus-certifications/levels-certification/basic-ip-1-certification) (accessed 2015 Dec. 2).
3. Blois B. Office-based ultrasound screening for abdominal aortic aneurysm. *Can Fam Physician* 2012;58:e172-8.