

## Country cardiograms case 56

Charles Helm, MD,  
CCFP  
Tumbler Ridge, BC

Correspondence to:  
Charles Helm;  
belm.c.w@gmail.com

This article has been peer  
reviewed.

**A** 75-year-old woman is brought by ambulance to a remote emergency department in the winter. She appears overwhelmingly distressed, having been assaulted by a family member and then having had to escape outside into the snow and run for help. She mentions that she is having

central chest pain. The electrocardiogram (ECG) shown in Figure 1 is recorded. What are the ECG findings, and what are the possible diagnoses?

**For the answer, see page 54.**

**Competing interests:** None declared.

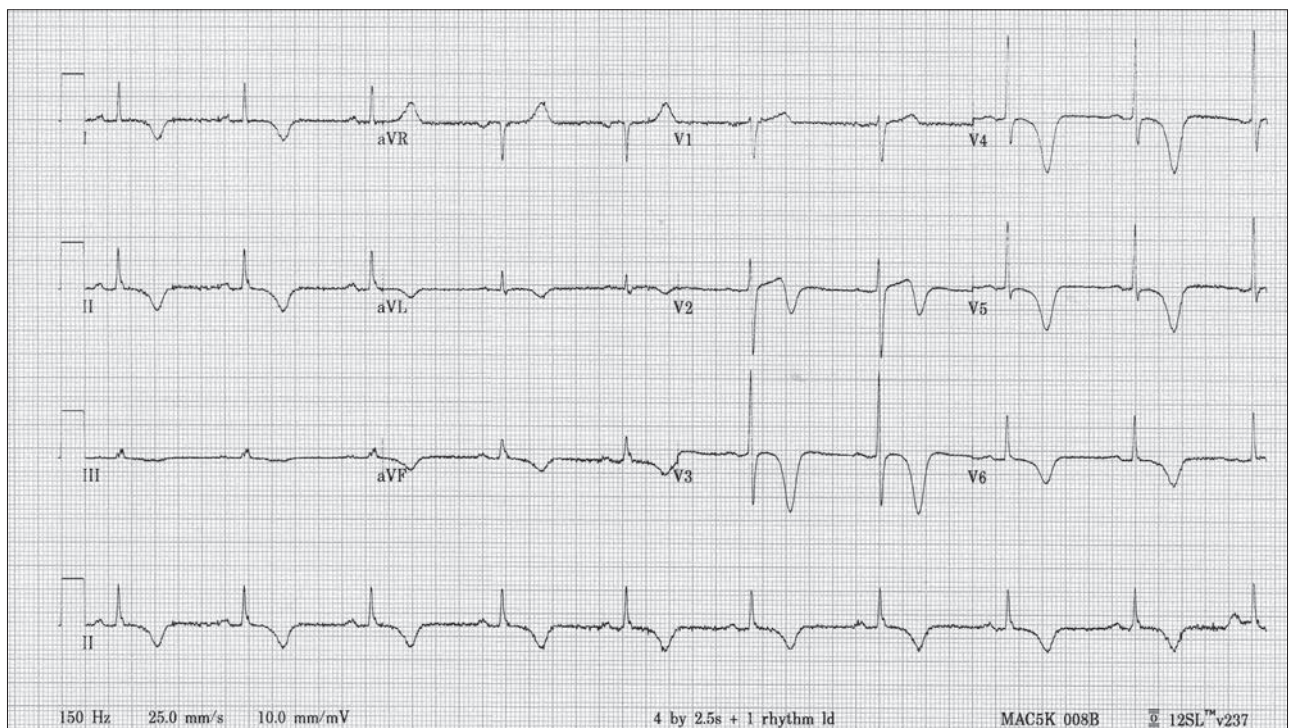


Fig. 1. Electrocardiogram of a 75-year-old woman with central chest pain.

“Country cardiograms” is a regular feature of *CJRM*. We present an electrocardiogram and discuss the case in a rural context. Please submit cases to Suzanne Kingsmill, *CJRM*, 45 Overlea Blvd., P.O. Box 22016, Toronto ON M4H 1N9; manedcjr@gmail.com.