

## Country cardiograms case 59

Charles Helm, MD,  
CCFP  
Tumbler Ridge, BC

Correspondence to: Charles  
Helm, helm.c.w@gmail.com

This article has been peer  
reviewed.

**A** 66-year-old man presents to a rural British Columbia emergency department with fatigue and dizziness. He is noted to have a slow pulse rate. He has had left bundle branch block on previous electrocardiograms. He takes diltiazem for treatment of

hypertension. The following tracing is recorded (Fig. 1). What is the interpretation, and what should be done?

**For the answer, see page 76.**

**Competing interests:** None declared.

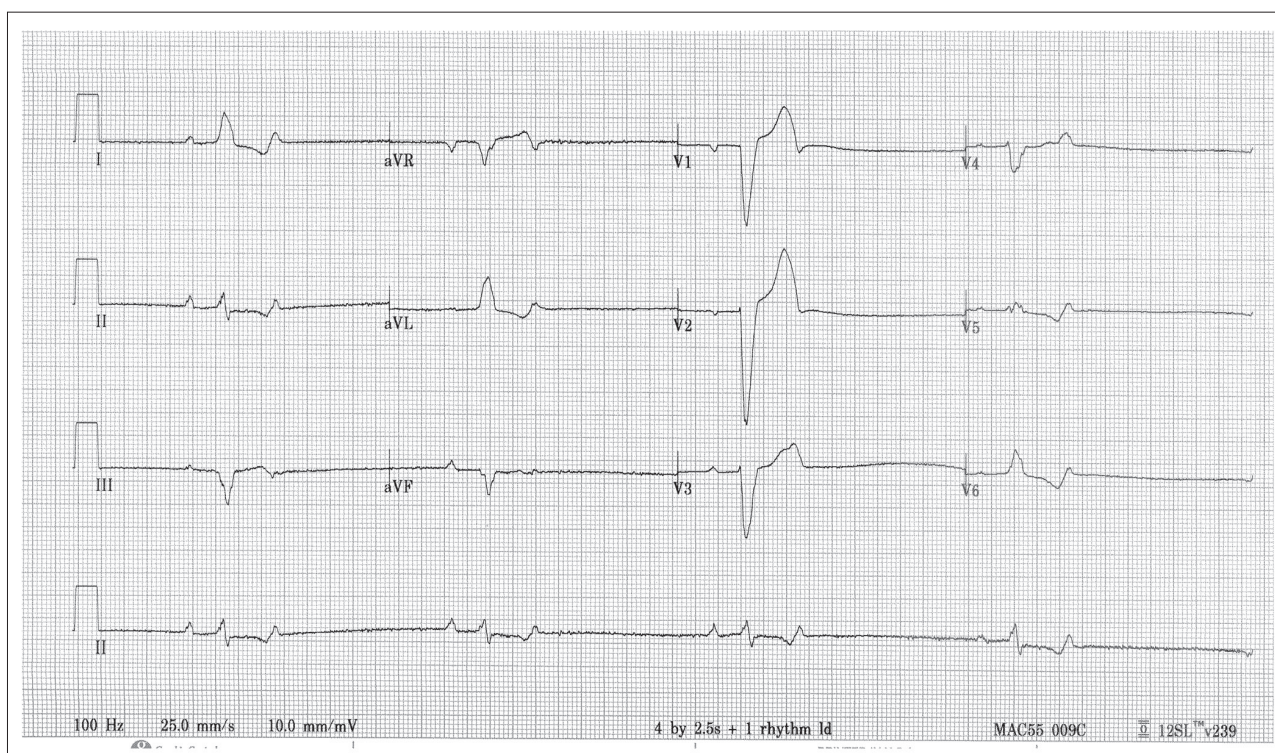


Fig. 1. Electrocardiogram of a 66-year-old man with fatigue, dizziness and a slow pulse rate.