

Country cardiograms case 62

Charles Helm, MD,
CCFP
Tumbler Ridge Health
Centre, Tumbler Ridge, BC

Correspondence to:
Charles Helm,
belm.c.w@gmail.com

This article has been peer
reviewed.

A 49-year-old woman presents to a remote Canadian emergency department with recent onset of palpitations and a sense of a racing heart. She has had 6 such episodes over the past 4 years. On 4 occasions, she found that she could terminate these events with coughing or bearing down. This is the second time that she has presented to the emergency department because of persistent symptoms; on the first occasion, her symptoms abruptly and spontaneously resolved

soon after arrival. A 12-lead electrocardiogram (ECG) is obtained (Fig. 1) and is essentially identical to the ECG that was obtained the previous time she presented. The computer interpretation reads: "Atrial fibrillation with rapid ventricular response, rate 157 per minute." What is your interpretation, and what are the implications for management?

For the answer, see page 56.

Competing interests: None declared.

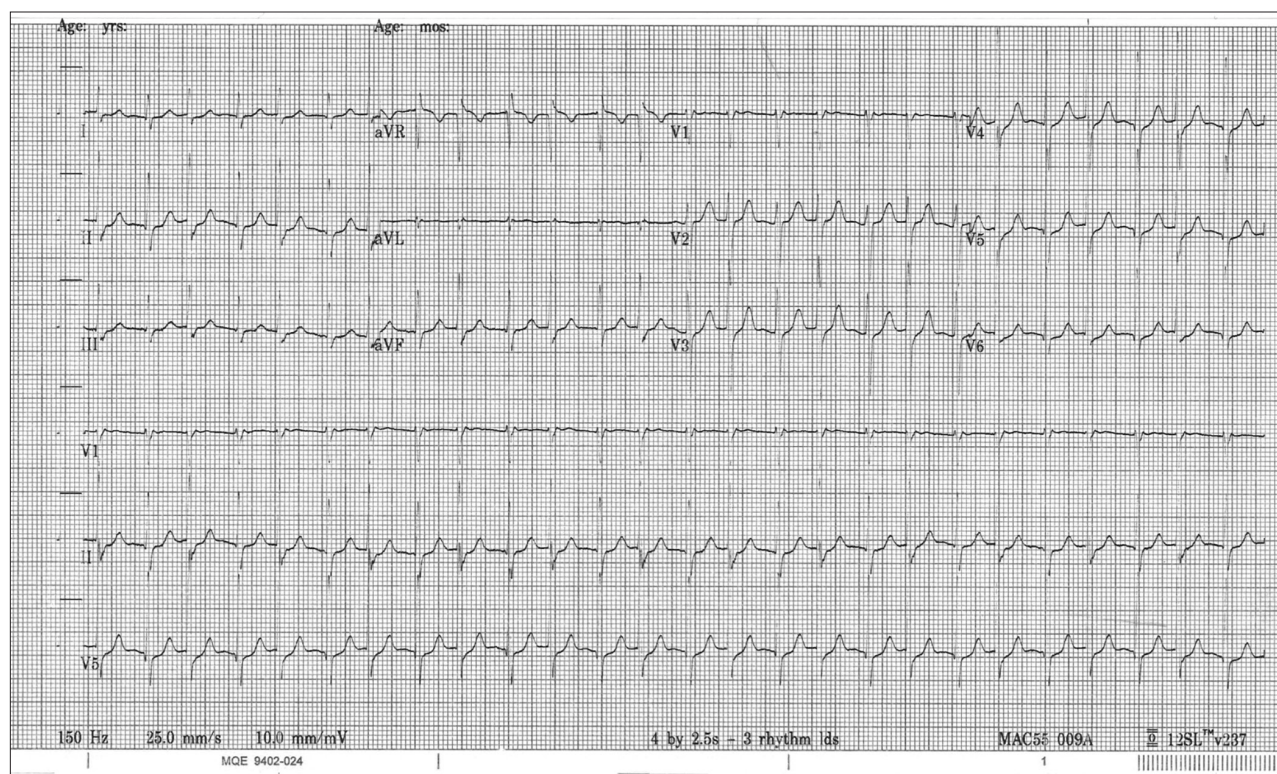


Fig. 1. Electrocardiogram of 49-year-old woman who presents to emergency department with recent onset of palpitations and sense of a racing heart.

"Country cardiograms" is a regular feature of *CJRM*. We present an electrocardiogram and discuss the case in a rural context. Please submit cases to Suzanne Kingsmill, *CJRM*, manedcjr@gmail.com.