

Country cardiograms case 64

Charles Helm, MD
 Tumbler Ridge Health Centre,
 Tumbler Ridge, BC

Correspondence to:
 Charles Helm,
 helm.c.w@gmail.com

This article has been peer reviewed.

An 80-year-old woman is brought to the emergency department of a remote Canadian health centre. She has multiple vague complaints: steadily increasing weakness, dizziness, poor balance, poor memory and generalized aches. Only basic laboratory results can be

obtained locally. As part of her investigations, electrocardiography is performed (Fig. 1). What is your interpretation, and what is a possible cause of her presentation?

For the answer, see page 117.

Competing interests: None declared.

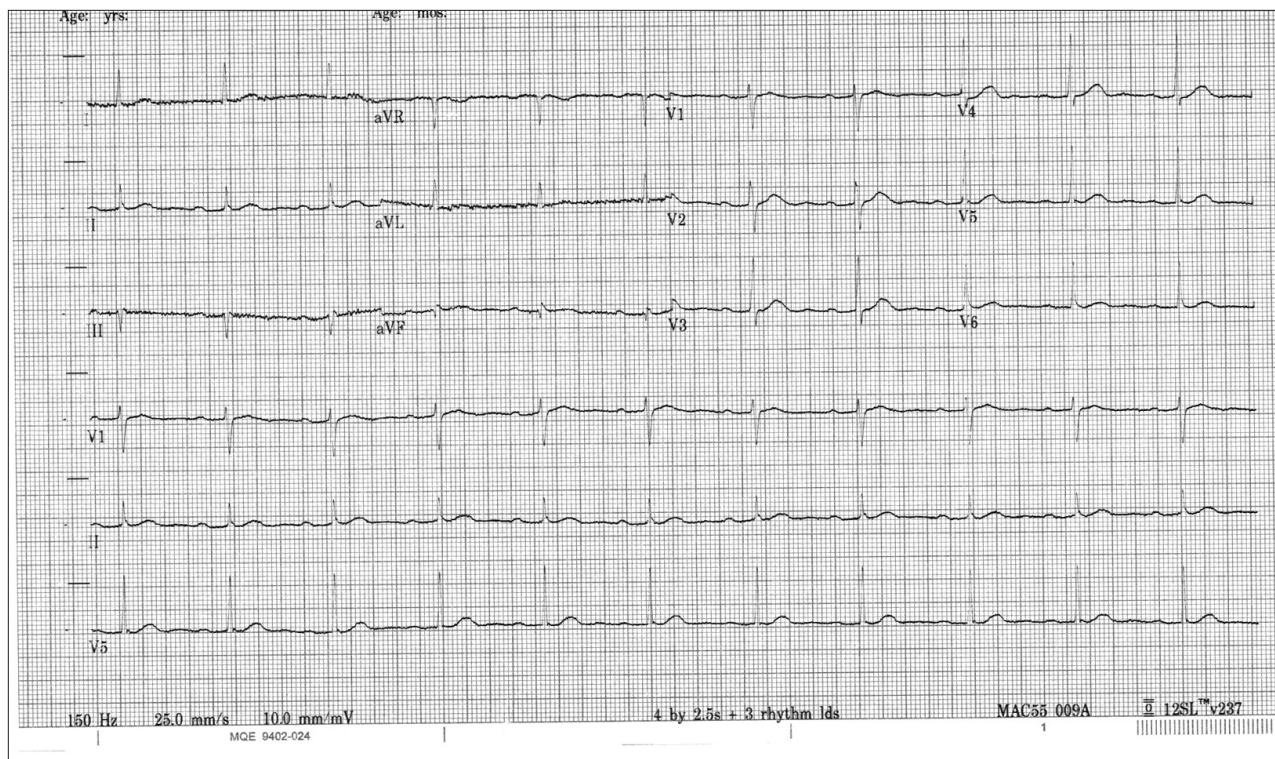


Fig. 1: Electrocardiogram of 80-year-old woman with multiple vague complaints.

“Country cardiograms” is a regular feature of *CJRM*. We present an electrocardiogram and discuss the case in a rural context. Please submit cases to Suzanne Kingsmill, *CJRM*, manedcjr@gmail.com.