

## Survival of Boerhaave syndrome against all odds at a rural Emergency Department

Mohammed Abraham,  
MD<sup>1</sup>, Janna AbdelAziz,  
BHSc<sup>2</sup>

<sup>1</sup>Assistant Clinical  
Professor (Adjunct),  
Division of Emergency  
Medicine, Department  
of Family Medicine,  
McMaster University,  
Hamilton, Ontario,  
Canada, <sup>2</sup>Department of  
Health Sciences, Carleton  
University, Ottawa, ON,  
Canada

Correspondence to:  
Mohammed Abraham,  
mabrahim@  
hamiltonhealthcare.com

This article has been peer  
reviewed

### INTRODUCTION

Boerhaave syndrome (BS) is rare, yet it is one of the most lethal emergencies. It is caused by a spontaneous full-thickness rupture of a previously healthy oesophagus following a sudden increase of the intra-oesophageal pressure against closed glottis.

BS was first accurately described in 1724 after a Dutch Physician, Hermann Boerhaave, performed a post-mortem autopsy on his friend's body to determine the cause of his sudden death.<sup>1</sup> Due to its high mortality rate, early diagnosis is crucial in determining a patient's survival. Rural and small hospital emergency departments (EDs) face a bigger challenge when diagnosing such time-sensitive emergencies due to the lack of after-hours advanced diagnostic and specialist coverage,<sup>2</sup> delayed inter-hospital transfers and response time of on-call staff. The authors present a rare case of BS survival under such extenuating circumstances in a rural ED.

### CASE REPORT

In January 2011, during a snowstorm, a 36-year-old male presented at

midnight to the ED of Milton District Hospital, a small town hospital in Ontario, Canada. The hospital had no in-house specialists or after-hours advanced diagnostic imaging. The only available doctor was a single emergency physician.

The patient described a 30-min history of nausea and vomiting followed by a sudden severe epigastric pain radiating to the back associated with dyspnoea and orthopnoea. He had no past medical history and was not on any medications.

On physical examination, he looked dyspnoeic with shallow rapid breathing, diaphoretic and orthopnoeic. His vital signs showed tachycardia, tachypnoea and he was afebrile. On chest auscultation, he had decreased air entry bilaterally and normal cardiac examination. He had severe abdominal tenderness with guarding mostly over the epigastrium. Electrocardiogram showed sinus tachycardia with no ischaemic changes.

The laboratory investigations were unremarkable. The initial chest radiograph performed at 1:30 am showed an extensive pneumomediastinum and a small

Received: 03-09-2020 Revised: 30-10-2020 Accepted: 18-11-2020 Published: 30-03-2021

This is an open access journal, and articles are distributed under the terms of the Creative Commons Attribution-NonCommercial-ShareAlike 4.0 License, which allows others to remix, tweak, and build upon the work non-commercially, as long as appropriate credit is given and the new creations are licensed under the identical terms.

For reprints contact: WKHLRPMedknow\_reprints@wolterskluwer.com

**How to cite this article:** Abraham M, AbdelAziz J. Survival of Boerhaave syndrome against all odds at a rural Emergency Department. Can J Rural Med 2021;26:87-90.

Access this article online
Quick Response Code:

Website: www.cjrm.ca
DOI: 10.4103/cjrm.cjrm_69_20

left-sided pleural effusion with atelectasis/consolidation at the base of the left lung [Figure 1]. Because the differential diagnosis of pneumomediastinum is broad and in order to reach a definitive diagnosis, we requested a computed tomography (CT) scan of the chest and abdomen. However, due to after-hours closure of the diagnostic facility, we called the on-call radiologist to approve our request. The on-call radiologist subsequently directed the on-call CT technician to drive to the hospital, and we were given a 30–45 min average wait time depending on the road conditions. Up to that time, the patient was stable; however, the intensity of the chest pain was increasing.

The CT scan of the chest [Figure 2] performed at 03:30 am revealed lower oesophageal perforation with left-sided moderate and right-sided small pleural effusion with dependent atelectasis associated with heterogeneous pulmonary density, possibly reflecting extensive pneumomediastinum extending into the lower neck. The abdominal CT scan showed no acute findings and helped to rule out intra-abdominal aetiology.

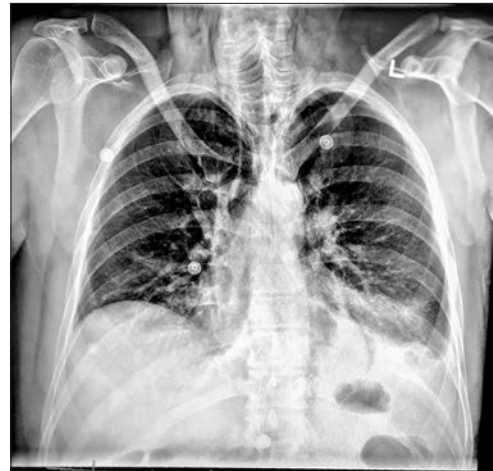The patient received intravenous hydration, analgesia and broad-spectrum antibiotics. The respiratory technician was also called in from home due to increased work of breathing and declining oxygen saturation of the patient.

After reaching the definitive diagnosis, the regional thoracic surgeon on call was consulted at a tertiary care centre, Toronto General Hospital, who recommended bilateral chest tube insertions prior to transfer. The local general surgeon was called in to assist with the chest tube insertion.

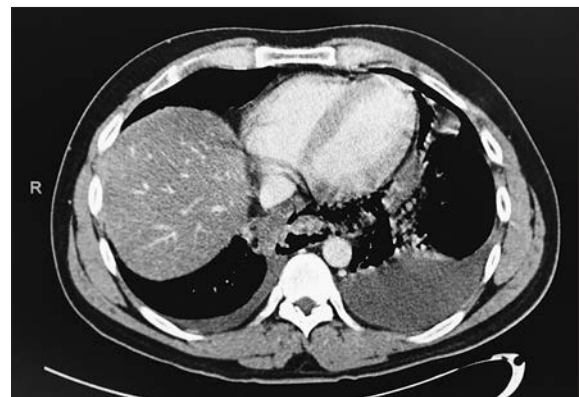
However, while inserting the first chest tube on the left side, the patient deteriorated into respiratory failure requiring emergency endotracheal intubation and mechanical ventilation. While securing the airway and initiating mechanical ventilation, the on-call general surgeon arrived and inserted two more chest tubes, which yielded serosanguinous fluid.

The last chest radiograph [Figure 3] was done at 7:30 am before transfer to tertiary care showing near-complete opacification of the left hemithorax, endotracheal tube in place with tip 2.9 cm superior to carina and bilateral chest tubes in place.

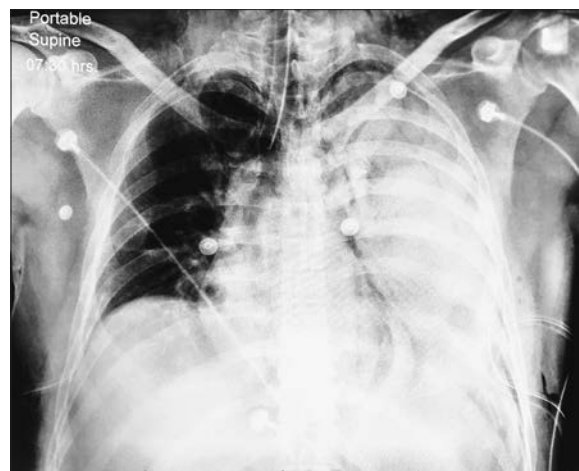
Due to the ongoing snowstorm, our request of transfer by air ambulance was denied. The patient was stabilized for transfer by land ambulance



**Figure 1:** Chest radiography demonstrating an extensive pneumomediastinum and a small left-sided pleural effusion with atelectasis/consolidation at the base of the left lung.



**Figure 2:** Chest computed tomography scan revealing a lower oesophageal perforation with left-sided moderate and right-sided small pleural effusion with dependent atelectasis associated with heterogeneous pulmonary density, possibly reflecting extensive pneumomediastinum extending into the lower neck.



**Figure 3:** Chest radiography showing near-complete opacification of the left hemithorax. Endotracheal tube in place with tip 2.9 cm superior to carina. Bilateral chest tubes in place.

and departed the ED at 9:30 am. The receiving thoracic surgeon performed an open pleural lavage and oesophageal repair. We followed the patient's course of therapy and met with him 2 years later to find him in great condition.

## DISCUSSION

Early diagnosis is crucial in determining the survival from BS as it carries a high mortality rate which increases sharply with delayed diagnosis and treatment. Every hour of delayed surgical treatment results in a 2% increase in mortality rate to virtually 100% if treatment is delayed by more than 48 h.<sup>3</sup>

It is crucial that BS is included in the differential diagnosis of patients presenting with chest or epigastric pain as one of the six fatal causes of chest pains that every emergency physician should think of first.<sup>4</sup>

Being aware that BS could deteriorate rapidly into respiratory failure and fatal shock, the rural emergency physician should make early diagnosis and early surgical intervention the most important factor in determining morbidity and mortality rate.

The classic presentation is described by Mackler's triad of vomiting, chest pain and subcutaneous emphysema; however, the triad is only present in <50% of cases.<sup>5</sup> Misdiagnosing BS is common, especially in the absence of advanced imaging. The most common diagnostic errors include perforated gastric or duodenal ulcer, myocardial infarction, pneumonia, acute pancreatitis, dissecting aortic aneurysm, pneumothorax, pulmonary embolism and renal colic.<sup>6</sup>

CT of the chest with intravenous and oral contrast provides greater diagnostic sensitivity and specificity. A CT scan is considered the diagnostic gold standard. However, only 17% of rural hospitals in the province of Ontario have access to a CT scanner.<sup>7</sup> The lack of access to local CT scanners imposes a significant burden on the physician's decision-making process in rural EDs. Research has shown that rural CT scanners change the area's quality of health care in significant ways and it helps to narrow the gap between rural and urban service levels.<sup>8</sup>

Therapeutic options are mostly based on open surgical repair as the most definitive

option. Recently, conservative and endoscopic treatments have been suggested in a very limited population according to the following criteria: (1) The oesophageal rupture is confined to the mediastinum; (2) The cavity is well drained into the oesophagus; and (3) the patient has minimal symptoms and no evidence of clinical sepsis.<sup>9</sup>

## CONCLUSION

This unique case represents survival against all odds by presenting with a severe case of BS to a rural ED with no in-house advanced diagnostic or surgical services, after midnight and during a Canadian winter. The patient of this reported case also suffered a rare, rapid deterioration into acute respiratory distress syndrome requiring emergency endotracheal intubation and bilateral chest tube insertions before out-of-hospital transfer to a tertiary care centre. Boerhaave's syndrome still represents a diagnostic and therapeutic challenge, especially for rural EDs. Timely diagnosis is the important prognostic determinant.

## Declaration of patient consent

The authors certify that they have obtained all appropriate patient consent forms. In the form the patient(s) has/have given his/her/their consent for his/her/their images and other clinical information to be reported in the journal. The patients understand that their names and initials will not be published and due efforts will be made to conceal their identity, but anonymity cannot be guaranteed.

**Financial support and sponsorship:** Nil.

**Conflicts of interest:** There are no conflicts of interest.

## REFERENCES

1. Derbes VJ, Mitchell RE Jr. Hermann Boerhaave's Atrocis, nec descripti prius, morbi historia, the first translation of the classic case report of rupture of the esophagus, with annotations. *Bull Med Libr Assoc* 1955;43:217-40.
2. Rourke JT. Trends in small hospital medical services in Ontario. *Can Fam Physician* 1998;44:2107-12.
3. Spapen J, De Regt J, Nieboer K, Verfaillie G, Honoré PM, Spapen H. Boerhaave's syndrome: Still a diagnostic and therapeutic challenge in the 21<sup>st</sup> century. *Case Rep Crit Care* 2013;2013:161286.
4. Rokicki M, Rokicki W. Samoistne pęknięcie przełyku. Zespół Boerhaave. *Pol Merkuriusz Lek* 1996;1:34850.

5. MACKLER SA. Spontaneous rupture of the esophagus; an experimental and clinical study. *Surg Gynecol Obstet* 1952;95:345-56.
6. Reamy BV, Williams PM, Odom MR. Pleuritic chest pain: Sorting through the differential diagnosis. *Am Fam Physician* 2017;96:306-12.
7. Fleet R, Pelletier C, Marcoux J, Maltais-Giguère J, Archambault P, Audette LD, *et al.* Differences in access to services in rural emergency departments of Quebec and Ontario. *PLoS One* 2015;10:e0123746.
8. Merckens BJ, Mowbray RD, Creeden L, Engels PT, Rothwell DM, Chan BT, *et al.* A rural CT scanner: Evaluating the effect on local health care. *Can Assoc Radiol J* 2006;57:224-31.
9. Cameron JL, Kieffer RF, Hendrix TR, Mehigan DG, Baker RR. Selective nonoperative management of contained intrathoracic esophageal disruptions. *Ann Thorac Surg* 1979;27:404-8.

## Advertising / Rural Medicine Careers / Classified and Recruitment

### Family Medicine in Beautiful Nisga'a Valley, BC

- Family Physicians needed to provide primary and urgent care for a population of 3,500 in four communities across the traditional Nisga'a Territory. A team of three physicians works together to provide full-scope services (excluding obstetrics) in concert with other services such as home care, public health, and mental wellness and addictions. The Health and Wellness Centers are staffed with full-time RNs who take first call after hours. Soaring mountains, picturesque fjords, dramatic lava beds, natural hot springs, and thriving rivers offer outstanding recreation year-round. Excellent remuneration. Contact Jeremy Penner at [md@nisgahealth.bc.ca](mailto:md@nisgahealth.bc.ca)

### ***SUMMER/FALL ONE WEEK LOCUM PLACEMENTS AVAILABLE IN NW ONTARIO – SCHREIBER & TERRACE BAY! NEW GRADUATES WELCOME***

We are looking for Rural family physician locums to visit one of one of our teams in **Terrace Bay and Schreiber this summer/fall**. Placements typically include 6 clinic days (typically starting on a Wednesday) and 3 or 4 ER on-call days. **Locum coverage includes clinic, ER and In-patient hospital/LTC duties. Current ACLS & ATLS preferred.**

We are part of the **North Shore Family Health Team** which includes a Nurse Practitioner, Dietician, Social Worker/Mental Health worker and Diabetes Nurse shared between our two clinics.

Patient volume for a typical day in clinic is 12-18 patients and currently (due to Covid) appointments are a mix of in-person and telephone assessments. Our emergency department is usually not overly busy and an average 24 hour period the on-call physician can expect 5-10 patients a day. Locum physicians are mainly paid through a daily stipend with some 3rd party and shadow billing. Clinic compensation is \$980 day with on-call (on-top of clinic!) being \$1,253/weekday and \$2,033/weekend & holidays. Travel reimbursed through HFO - \$500 travel days + flights, car rental, accommodations!

Schreiber and Terrace Bay are located at the top of Lake Superior in Northwestern Ontario. We have a beautiful 3 bedroom locum house which can accommodate your partner/family! Enjoy our great outdoors this summer!

Contact Cheryl at [phy.recruiter@nosh.ca](mailto:phy.recruiter@nosh.ca) for dates and details!

Welcome to beautiful NW Ontario