Procedural Article

The occasional cervical biopsy

Julia Robson, BSc,[1] Cara van der Merwe, BHSc[1], Leslea Walters, MD, FRCSC[2,3,4], Laura Noack, MD, CCFP[4,5], Sarah M. Giles MD, CCFP (EM)[4,5,6]

[1]Faculty of Health Sciences, School of Medicine, Queen's University, Kingston, Ontario, Canada, [2]Winnipeg Health Sciences Centre, Women's Hospital, Winnipeg, Manitoba, Canada, [3]Department of Obstetrics and Gynecology, Rady College of Medicine, University of Manitoba, Winnipeg, Manitoba, Canada, [4]Lake of the Woods District Hospital, Kenora, Ontario, Canada, [5]Department of Family Medicine, Faculty of Medicine, Northern Ontario School of Medicine, Thunder Bay, Ontario, Canada, [6]Department of Family Medicine, Faculty of Medicine, University of Ottawa, Ontario, Canada

Correspondence to: Sarah M. Giles, smgiles@dal.ca

This article has been peer reviewed.

Access this article online

Quick Response Code:

Website: www.cjrm.ca

DOI: 10.4103/cjrm.cjrm_13_21

INTRODUCTION

The rates of cervical cancer in Canada, as well as the associated morbidity and mortality, have decreased substantially over the past 40 years thanks to screening programmes and human papilloma virus (HPV) vaccination programmes.[1,2] The success of these programmes still relies on screening for early cervical cancer through Papanicolaou (Pap) smears, cervical biopsies, and increasingly, HPV testing. The Canadian Task Force on Preventive Health Care recommends initiating cervical screening at the age of 25 years and many provinces have adjusted their guidelines to reflect this evidence.[3] Pap smears are screening tests for asymptomatic patients with the aim of identifying patients who require colposcopy and biopsies. As soon as an abnormality is seen, a biopsy is indicated – it is insufficient to only perform a Pap smear on a patient who is symptomatic or who has an abnormal cervix. While abnormal Pap smear results generally lead to colposcopy, in the setting of an obvious abnormality, cervical biopsy remains firmly within the scope of primary care physicians[4] as biopsy may expedite management of precancerous or cancerous lesions, and can also reduce overtreatment by identifying abnormalities that can be followed over time.[5] Further, family physicians with sufficient colposcopy training, as well as available equipment and facilities, may perform colposcopy.

WHEN TO BIOPSY?

The indications for a cervical biopsy include abnormalities in the cervix on inspection or palpation. A Pap test with repeated unexplained inflammation, atypical squamous cells of unknown significance or consistent with a low-grade squamous intraepithelial lesion (LSIL) or a high-grade squamous intraepithelial lesion (HSIL) is an indication for colposcopy.[6,7] Generalists should biopsy grossly abnormal cervical lesions to speed diagnosis. If HPV testing is available, results should be incorporated into the risk assessment and course of action.[8]

The most common type of biopsy used to collect specimens from the cervix is a punch biopsy. However, the location of the lesion, suspected grade of abnormality and previous procedures all influence which method is selected.[8] A curette can be used to obtain an endocervical biopsy. Alternatively, a cone biopsy is considered to be a form of excisional treatment because it removes the transformation zone but would require referral to a specialist.[8]

Received: 25-02-2021 **Revised:** 24-06-2021 **Accepted:** 11-07-2021 **Published:** 26-03-2022

How to cite this article: Robson J, van der Merwe C, Walters L, Noack L, Giles SM. The occasional cervical biopsy. Can J Rural Med 2022;27:72-6.

COLPOSCOPY IN PRIMARY CARE AND TELECOLPOSCOPY

Abnormal cervical biopsy results may lead to a colposcopist referral. Colposcopy is part of approximately 12% of American family physicians' practices.[9] While similar statistics are not currently available for Canada, colposcopy training may be offered as part of residency programmes or as an additional certification. The American Society for Colposcopy and Cervical Pathology and Society of Obstetricians and Gynaecologists of Canada run excellent courses and provide initial training for primary care practitioners interested in becoming colposcopists. As there is no formal standard, however, being able to perform colposcopy in the primary care setting depends on physician training, comfort level, equipment availability, staff support, and the needs of the local community.[9]

There is also an emerging literature on telecolposcopy, which may have a place in assisting rural physicians whose patients would otherwise have to travel unreasonably long distances to see a colposcopist. Using telecolposcopy could potentially reduce costs and improve patient outcomes.[10] Additionally, preliminary research found that telecolposcopy may be just as acceptable to patients as traditional colposcopy.[11]

CONTRAINDICATIONS, RISKS, AND BENEFITS OF CERVICAL BIOPSY

Relative contraindications to cervical biopsy include late pregnancy or active labour, active cervical or vaginal infection, any of which can increase the likelihood of bleeding or infection, increase spurious findings, and/or decrease the sensitivity and specificity of the biopsy.[7] If a patient is palliative a cervical biopsy cannot be justified. Finally, if a patient does not consent to a cervical exam or biopsy, that is an absolute contraindication to these procedures. The risks associated with cervical biopsy include pain, bleeding, infection, and psychological distress.[5] Some of the benefits of cervical biopsy include early identification and management of intraepithelial lesions.[5]

EQUIPMENT

- Sterile Gloves
- Speculum
- Lubricant
- Light source
- Poviodine 10% solution
- Normal saline
- Cotton balls/swabs
- Ring forceps
- Lidocaine spray/lignocaine gel
- Endocervical curette
- Cytobrush
- Cervical punch biopsy forceps
- 3.0 non-braided dissolvable suture material
- Needle drivers
- Scissors
- Forceps
- Monsel's paste (you can make your own if you have difficulty ordering it)[13]
- Labelled specimen jar containing formalin
- Pencil to draw and label lesions and biopsy sites
- Pads for the patient after the procedure.

PROCEDURE

If the biopsy is planned, patients may be instructed to take ibuprofen/naproxen/acetaminophen the night before and the morning of the cervical biopsy to reduce pain. Biopsies cause mild to moderate pain, especially in women with a prior history of dysmenorrhea, so consideration of pain control strategies in advance is important.[15]

1. When obtaining a routine Pap smear, be ready to opportunistically biopsy lesions that you might find. It may be useful to have a gyne caddy set-up that can be brought into the room immediately should a specimen need to be collected
2. Obtain informed consent prior to the procedure and give the patient the option of having a chaperone attend the procedure. Some patients find that music during the procedure may help reduce anxiety[16]
3. Prepare necessary tools and solutions from the above list, including those needed for the cervical biopsy itself. Warm the smallest effective speculum with water if it is made of metal. Ask the patient to lie in the dorsal lithotomy position
4. Begin by examining the vulva for lesions or other abnormalities. Perform a bimanual exam if not done at or around the time the le-

sion was found. Examine the inguinal region to identify any abnormal lymph nodes or other masses[7]

5. Insert the speculum gently, wipe away mucous using a cotton swab or gauze held by ring forceps
6. Examine the cervix for signs of infection and inflammation. In addition, inspect for any cervical abnormalities[7] If indicated, and the patient has consented, swab for gonorrhoea and chlamydia at this point (or collect a urine sample after the exam)
7. Although the literature remains incomplete and is sometimes contradictory, recent research suggests that topical lidocaine spray applied to the cervix or topical lignocaine gel may be effective in reducing pain during the procedure when compared to forced cough or injected local anesthesia.[17-19] The strategy used for pain control should depend on patient preference, local availability, and provider experience. Intracervical anaesthetic injection may increase procedure time and cause pain with injection, and it is not yet clear whether it decreases overall procedure-related pain.[20,21] However, a lack of topical pain control should not prevent a biopsy. Many clinicians do not use anaesthesia and, instead, distract the patient by asking them to cough
8. To evert the os one may use a cotton tipped swab
9. Characterize abnormal zones of the cervix for later documentation based on their percentage size and 'clock position' on the cervix. In particular, the features of each lesion as well as details of their margins should be noted
10. Apply poviodine to the cervix using cotton swabs or gauze held in ring forceps
11. If there is a cervical polyp where the base of the stalk can be seen, simply grasp the polyp as close to the base as possible with ring forceps and twist until it detaches. Do not do this if the patient is on an anti-coagulant. If the stalk is not visible, consider referral
12. For lesions appearing to extend into the endocervical canal, perform an endocervical curettage using an endocervical curette. Use the endocervical curette to scrape all the way around the endocervical canal and put the tissue from the curette into formalin. Use a cytobrush to pick-up the remaining tissue in the endocervical canal. If an endocervical curette is not available, sample the tissue using a cytobrush. Rotate the cytobrush approximately five times in the endocervical canal. For large lesions, a wedge piece can simply be cut out with a scalpel. Once the sample has been obtained, the tip can then be removed and dropped into the formalin suspension
13. Using Tischler forceps if available, begin with any area on the posterior aspect of the cervix that appears abnormal to avoid bleeding that may obscure anterior sites. Place the 'fixed jaw' portion of the forceps on the "os side" of the lesion, with the other portion placed on the posterior aspect of the cervix. Each biopsy should be approximately 3 mm deep.[7] If Tischler forceps are not available, simply use a small scalpel to obtain a tissue sample. Additional cutting and rotation should be avoided.[22] Continue to biopsy any additional lesions, using a cotton swab to control any bleeding that obscures visibility. If possible, take at least two biopsies, including the most abnormal-looking lesion.[4,23-26] All biopsies can be placed in the same specimen container containing 10% formalin[4] [Figures 1 and 2].
14. After all biopsies are completed, apply Monsel's paste to areas that continue to ooze.[27] If Monsel's paste is not available, apply pressure for 3 min. If bleeding cannot easily be controlled, place a suture using 3.0 absorbable suture material. Once bleeding is satisfactorily controlled, gently remove the

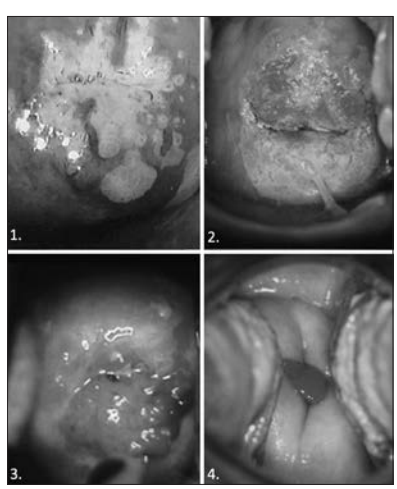

Figure 1: Examples of cervical pathology including atypical squamous cell of the cervix (1), high-grade squamous intraepithelial lesion (2), invasive squamous cell of the cervix (3), and a cervical polyp (4).[12]

Figure 2: Image depicts Tischler biopsy forceps, which are used to obtain biopsies of the cervix.[14]

speculum, inspecting the vaginal walls for any abnormalities. For unexpected heavy bleeding, place gauze soaked in Monsel's solution up against the lesion and then pack the vagina with packing material (such as Kerlex gauze) with as much packing as possible to apply pressure and then reassess bleeding frequently. If the bleeding is going through the packing, the patient's vitals are unstable, or you are concerned, call the nearest centre with an on-call gynaecologist for advice. Re-drape and offer the patient a wipe and pad

15. Document details of the exam and draw and label a diagram of the patient's cervix to detail the locations of lesions as well as the sites that were biopsied
16. A vasovagal response may occur after the procedure, so ask the patient to remain supine for a few minutes prior to asking them to sit and then stand slowly.

After the procedure

Inform the patient that for hours to days after the procedure, dark/black-appearing Monsel's paste and clotted blood (similar in consistency to coffee grounds) may be discharged from the vagina.[6,7] For pain and/or cramping after the procedure, suggest and make sure the patient has access to ibuprofen, naproxen or acetaminophen. Also advise the patient on signs of potential infection and when to return for additional evaluation (any of pelvic pain, fever, foul odour, discharge and bleeding that requires more than a thin pad). Patients should avoid tampons, douching (for which there is never an indication) and intercourse for 1–2 weeks after the procedure. Indicate initial impression, when the patient should expect results, and what will happen next.

CONCLUSION

When the appropriate equipment is available, primary care-based cervical biopsy can accelerate appropriate management of suspected cervical cancer.[5]

Financial support and sponsorship: Nil.

Conflicts of interest: There are no conflicts of interest.

REFERENCES

1. Mosavi-Jarrahi A, Kliewer EV. Cervical cancer incidence trends in Canada: A 30-year population-based analysis. J Obstet Gynaecol Can 2013;35:620-6.
2. Canadian Cancer Statistics Advisory Committee. Canadian Cancer Statistics 2019. Toronto, ON: Canadian Cancer Society; 2019.
3. Phillips SP, Bates S, Mavriplis C, Greiver M, Patel T, Hayes MJ, *et al*. Cervical cancer screening for young women. First do no harm. Can Fam Physician 2020;66:14-8.
4. Burness JV, Schroeder JM, Warren JB. Cervical colposcopy: Indications and risk assessment. Am Fam Physician 2020;102:39-48.
5. Khan MJ, Werner CL, Darragh TM, Guido RS, Mathews C, Moscicki AB, *et al*. ASCCP colposcopy standards: Role of colposcopy, benefits, potential harms, and terminology for colposcopic practice. J Low Genit Tract Dis 2017;21:223-9.
6. Denise DW. Laboratory and diagnostic tests – Cervical biopsy (Punch Biopsy, Endocervical Curettage, Cone Biopsy, Cervical Conization, Loop Electrosurgical Excision Procedure). New York: The McGraw-Hill Companies, Inc., The Professional Book Group; 2008. p. 143.
7. Mayeaux EJ Jr., editor. Colposcopy and directed cervical biopsy. In: Essential Guide to Primary Care Procedures. 2nd ed., Ch. 74. Philadelphia, PA: Lippincott Williams & Wilkins; 2015. p. 576-87.
8. Perkins RB, Guido RS, Castle PE, Chelmow D, Einstein MH, Garcia F, *et al*. 2019 ASCCP risk-based management consensus guidelines for abnormal cervical cancer screening tests and cancer precursors. J Low Genit Tract Dis 2020;24:102-31.
9. N.d.; Colposcopy (Position Paper). American Academy of Family Physicians (AAFP). Available from: https://www.aafp.org/about/policies/all/colposcopy-position-paper.html. [Last accessed on 2021 Feb 21].
10. Murugesu S, Galazis N, Jones BP, Chan M, Bracewell-Milnes T, Ahmed-Salim Y, *et al*. Evaluating the use of telemedicine in gynaecological practice: A systematic review. BMJ Open 2020;10:e039457.
11. Ferris DG, Litaker MS, Gilman PA, Leyva Lopez AG. Patient acceptance and the psychological effects of women experiencing telecolposcopy and colposcopy. J Am Board Fam Pract 2003;16:405-11.
12. Brookside Associates Endocervical Polyp, Moderate Dysplasia of Cervix, High Grade Lesion of Cervix, & Invasive Squamous Cell Carcinoma. Available from: https://brooksidepress.org/Products/OBGYN_101/MyDocuments4/Text/CervicalDisease/cervical_disease_and_neoplasia.htm. [Last accessed on 2021 Jan 05].
13. Comprehensive Cervical Cancer Control: A Guide to Essential Practice. 2nd ed. Geneva: World Health Organization; 2014. Annex 13, How to Make Monsel's Paste. Available from: https://www.ncbi.nlm.nih.gov/books/NBK269598/. [Last accessed on 2021 Feb 21].
14. Basu P, Sankaranarayanan R. Atlas of Colposcopy – Principles and Practice: IARC CancerBase No. 13. Lyon, France: International

Agency for Research on Cancer; 2017. Available from: https://screening.iarc.fr/atlascolpo.php. [Last accessed on 2021 Feb 24].
15. Kim K, Lee B, Park Y, Suh DH, No JH, Kim YB. Factors affecting pain during outpatient clinic based surgical procedures in gynecologic oncology. Medicine (Baltimore) 2018;97:e11721.
16. Galaal K, Bryant A, Deane KH, Al-Khaduri M, Lopes AD. Interventions for reducing anxiety in women undergoing colposcopy. Cochrane Database Syst Rev 2011;2011:CD006013.
17. Wongluecha T, Tantipalakorn C, Charoenkwan K, Srisomboon J. Effect of lidocaine spray during colposcopy-directed cervical biopsy: A randomized controlled trial. J Obstet Gynaecol Res 2017;43:1460-4.
18. Karaman E, Kolusarı A, Alkış İ, Çetin O. Comparison of topical lidocaine spray with forced coughing in pain relief during colposcopic biopsy procedure: A randomised trial. J Obstet Gynaecol 2019;39:534-8.
19. Zutshi V, Seshan V, Yadav A. Comparison of lignocaine spray versus lignocaine gel for pain relief during colposcopic directed cervical biopsy. Indian J Gynecol Oncol 2020;18:115.
20. Bogani G, Serati M, Cromi A, Di Naro E, Casarin J, Pinelli C, *et al*. Local anesthetic versus forced coughing at colposcopic-guided biopsy: A prospective study. Eur J Obstet Gynecol Reprod Biol 2014;181:15-9.
21. Kiviharju M, Kalliala I, Nieminen P, Dyba T, Riska A, Jakobsson M. Pain sensation during colposcopy and cervical biopsy, with or without local anesthesia: A randomized trial. J Low Genit Tract Dis 2017;21:102-7.
22. World Health Organization. WHO Guidelines for Screening and Treatment of Precancerous Lesions for Cervical Cancer Prevention. Geneva: World Health Organization; 2014.
23. Bentley J. SOGC/SCC Clinical Practice Guideline: Colposcopic Management of Abnormal Cervical Cancer Screening and Histology; 2017. https://secureservercdn.net/160.153.138.53/o4s.970.myftpupload.com/wp-content/uploads/2017/10/Colposcopy-Guidelines-FINAL-2012-02-19.pdf. [Last accessed on Feb 19].
24. Gage JC, Hanson VW, Abbey K, Dippery S, Gardner S, Kubota J, *et al*. Number of cervical biopsies and sensitivity of colposcopy. Obstet Gynecol 2006;108:264-72.
25. Nakamura Y, Matsumoto K, Satoh T, Nishide K, Nozue A, Shimabukuro K, *et al*. Optimizing biopsy procedures during colposcopy for women with abnormal cervical cancer screening results: A multicenter prospective study. Int J Clin Oncol 2015;20:579-85.
26. Baasland I, Hagen B, Vogt C, Valla M, Romundstad PR. Colposcopy and additive diagnostic value of biopsies from colposcopy-negative areas to detect cervical dysplasia. Acta Obstet Gynecol Scand 2016;95:1258-63.
27. Hilal Z, Rezniczek GA, Tettenborn Z, Hefler LA, Tempfer CB. Efficacy of monsel solution after cervical biopsy: A randomized trial. J Low Genit Tract Dis 2016;20:312-6.