Cancer Immunotherapy and its Complications

Cornelius Woelk MD, CCFP(PC), FCFP
Medical Director of Palliative Care – Southern Health-Santé Sud
Medical Director – Boundary Trails Regional Cancer Program
Family Physician – Winkler, MB

Specific Learning Objectives

- Describe the basics of the immune system's involvement in tumour control.
- Recognize the constellation of signs and symptoms for which immune-related adverse events (irAE) should be considered in the differential diagnosis.
- Explain the work up of suspected irAEs of the endocrine system, skin, GI tract, lung and liver.
- Describe those circumstances in which the primary care clinician should initiate urgent communication with the medical oncologist of a patient who is being or has been treated with an immune checkpoint inhibitor.

Disclosure of Conflicts

- Relationships with commercial interests:
  - Grants/Research Support: NONE
  - Speakers Bureau/Honoraria: NONE
  - Consulting Fees: NONE
  - Other: NONE
- No financial incentives
- No pharmaceutical affiliation
- Medical Consultant with *Canadian Virtual Hospice*
- Pictures may be subject to copyright
- No off-label pharmaceutical suggestions will be made

Special Credit

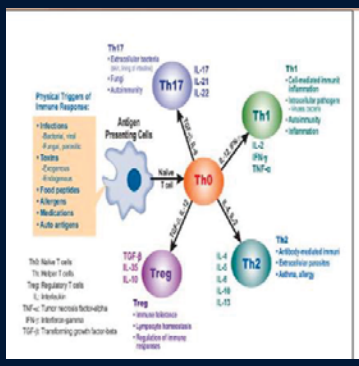

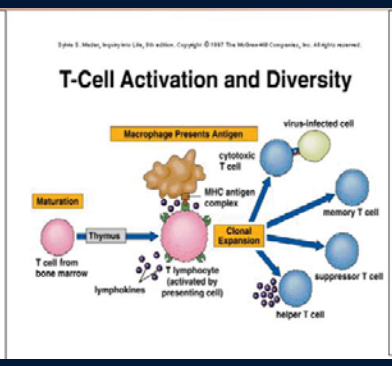

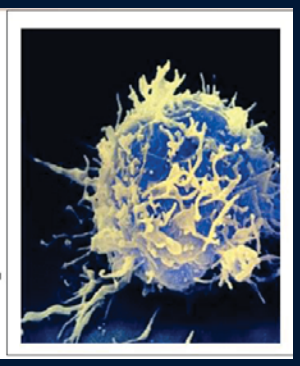

An *Early Diagnosis Workshop* by: CancerCare Manitoba COMMUNITY ONCOLOGY PROGRAM

Growth in Potential Cancer Treatments

- Surgery
- Radiation
- Hormone Therapy
- Chemotherapy
- Targeted Therapy
- Immunotherapy
- Stem Cell Transplantation
- Precision Medicine

Case 1 – Mr. G

- 2012 - 58 yr old man with 1.5 cm mobile preauricular nodule, biopsy positive for malignant melanoma
- Metastatic workup normal apart from subarachnoid cyst
- Nodule became smaller, and he was lost to follow up

- 2013 – repeat staging – negative
- “Spontaneously Regressed Intraparotid Malignant Melanoma”

Case 1 – Mr. G

- March 2014 – wide excision, superficial parotidectomy, neck dissection
- Scar, suggestive of regressed melanoma
- Unremarkable parotid tissue
- Multiple compound melanocytic nevi
- 42 nodes – all negative for melanoma

Case 1 – Mr. G

- March 2017 – laparotomy for a small bowel obstruction, suspected tumour
- Pathology positive for malignant melanoma

- July 2017 – new hepatic lesions

- August 2017
- Stage IV BRAF mutated metastatic melanoma with liver metastases
- Rx: Dabrafenib 150 mg po BID and Trametinib 2 mg po daily
- Tolerated well; October scans showed improvement

Case 1 – Mr. G

- April 2018 – routine CT shows deterioration in abdomen with development of multiple large centrally necrotic intraabdominal nodes, up to 4.5 cm diameter

Case 1 – Mr. G

- May 2018 – Pembrolizumab IV q3weeks

Immune System and Cancer Control

- The immune system has the greatest potential for the specific destruction of tumours with no toxicity to normal tissue and for long-term memory that can prevent cancer recurrence
- Immunosurveillance depends on the recognition of tumour antigens
- Malignant progression is accompanied by profound immune suppression that interferes with an effective antitumour response and tumour elimination.

Finn OJ. Immuno-oncology: understanding the function and dysfunction of the immune system in cancer. Annals of Oncology 2012;23 (Supplement 8): viii6–viii9.

Innate and Adaptive Immunity

Non-specific Immunotherapy

- Uses cytokines, growth factors and other substances to give the immune system a boost to fight cancer
- Cytokines trigger the immune system to fight bacteria, viruses, and disease
- Cytokines can also be made in the lab and used to treat cancer

- **Interferon alfa** - melanoma
- **Interleukin-2** - kidney cancer and melanoma
- **Bacillus Calmette-Guerin (BCG)** - early-stage bladder cancer

Preparing the Immune Response

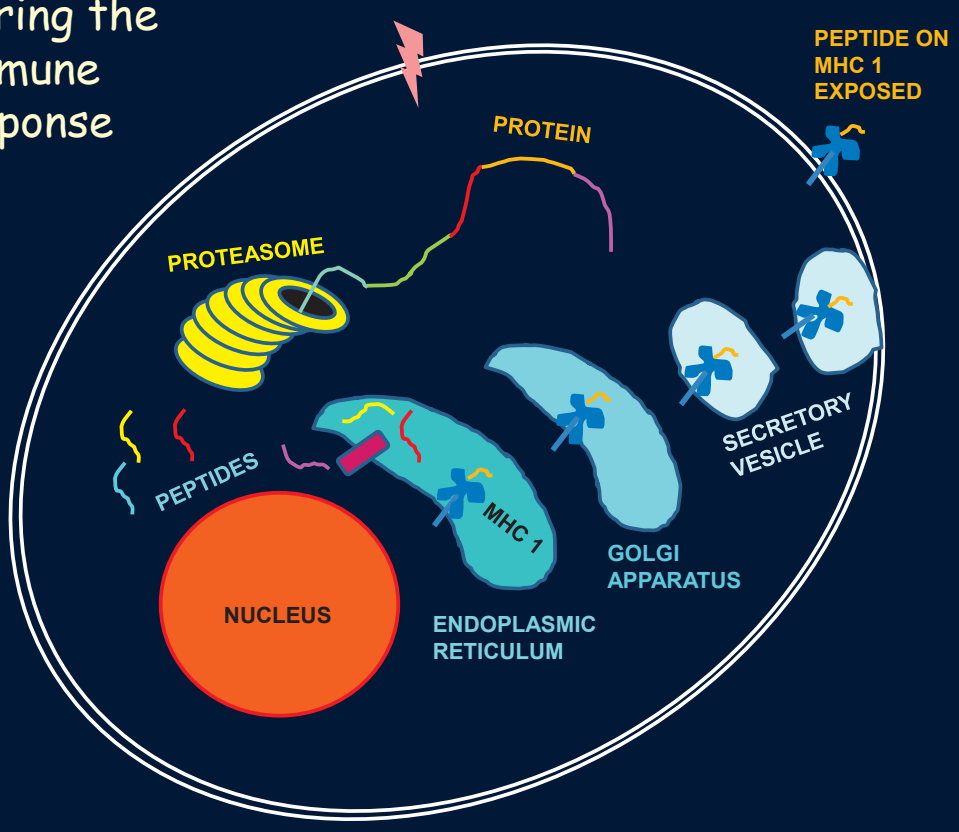

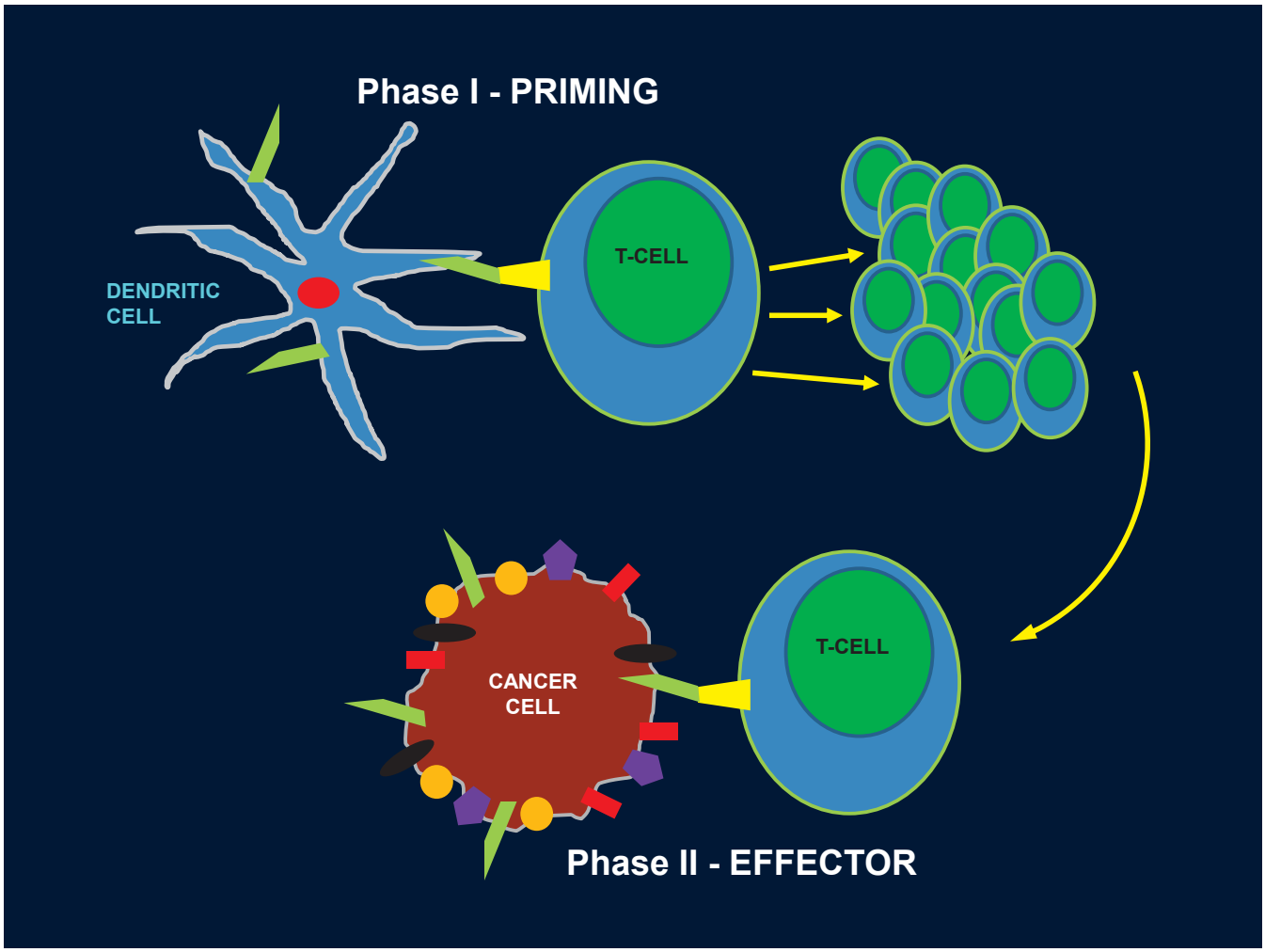
Phase I - PRIMING
DENDRITIC CELL
T-CELL
CANCER CELL
T-CELL
Phase II - EFFECTOR

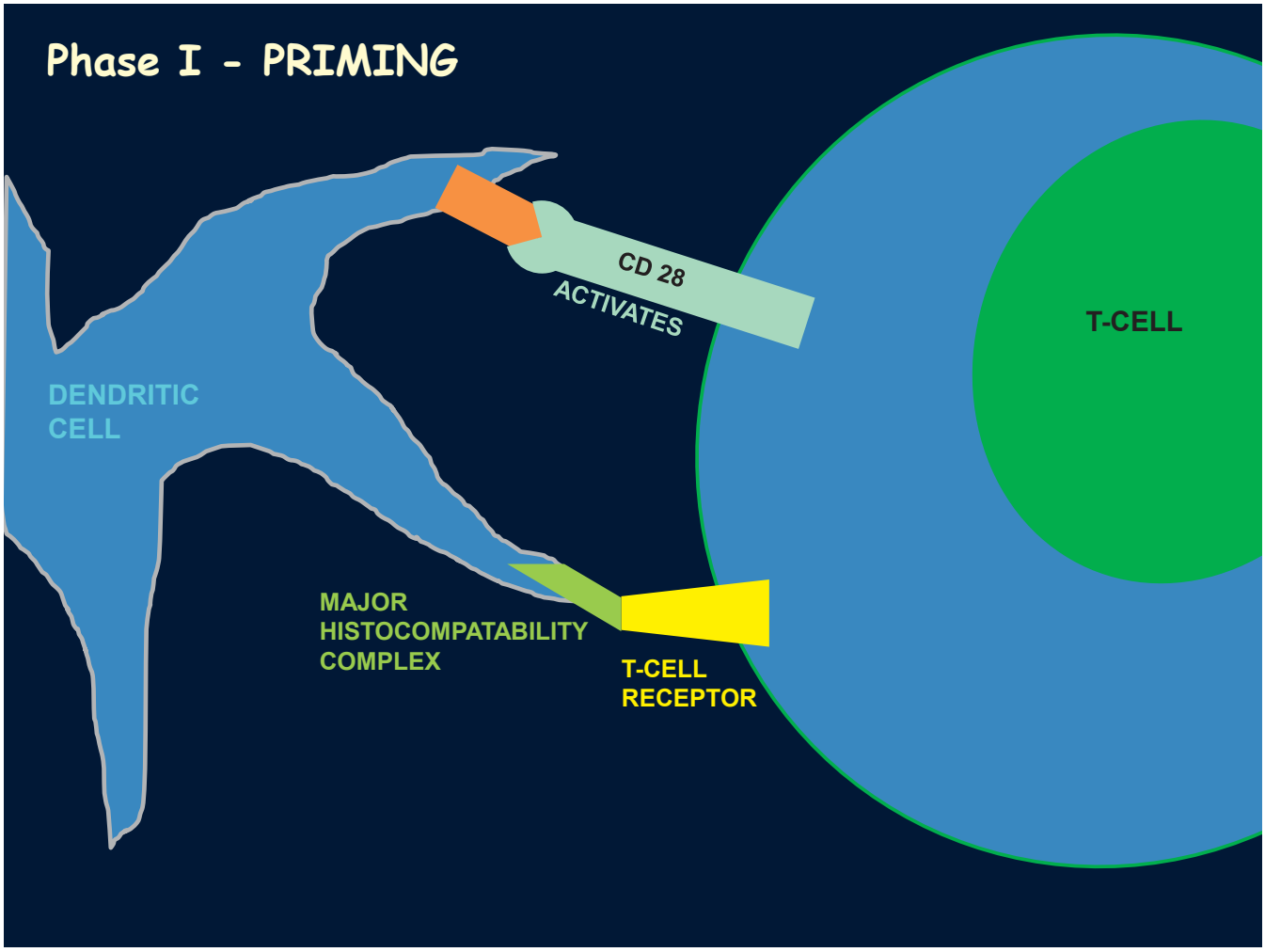
Phase I - PRIMING
CD 28
ACTIVATES
T-CELL
DENDRITIC CELL
MAJOR HISTOCOMPATABILITY COMPLEX
T-CELL RECEPTOR

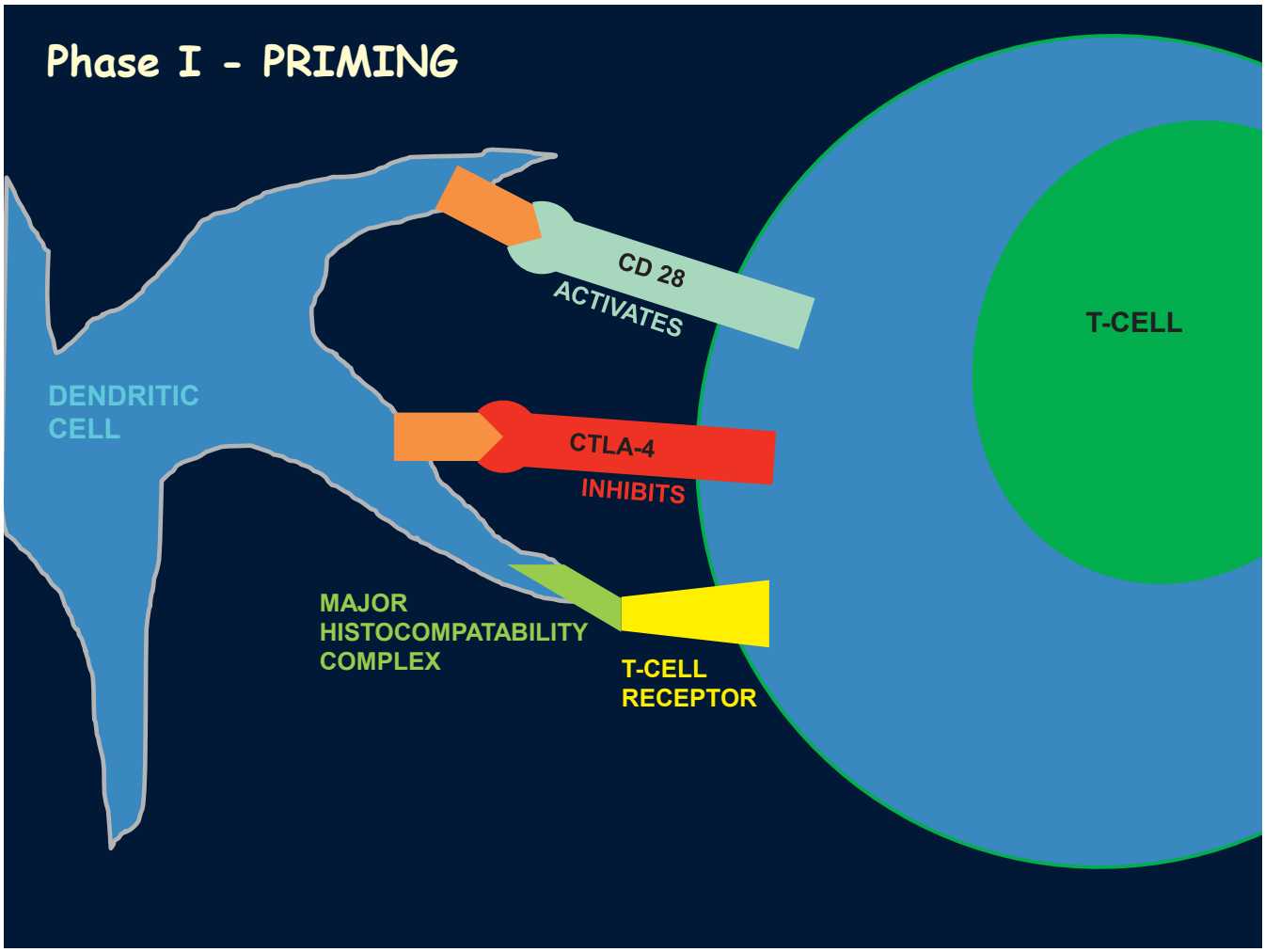
Phase I - PRIMING
CD 28
ACTIVATES
T-CELL
DENDRITIC
CELL
CTLA-4
INHIBITS
MAJOR
HISTOCOMPATABILITY
COMPLEX
T-CELL
RECEPTOR

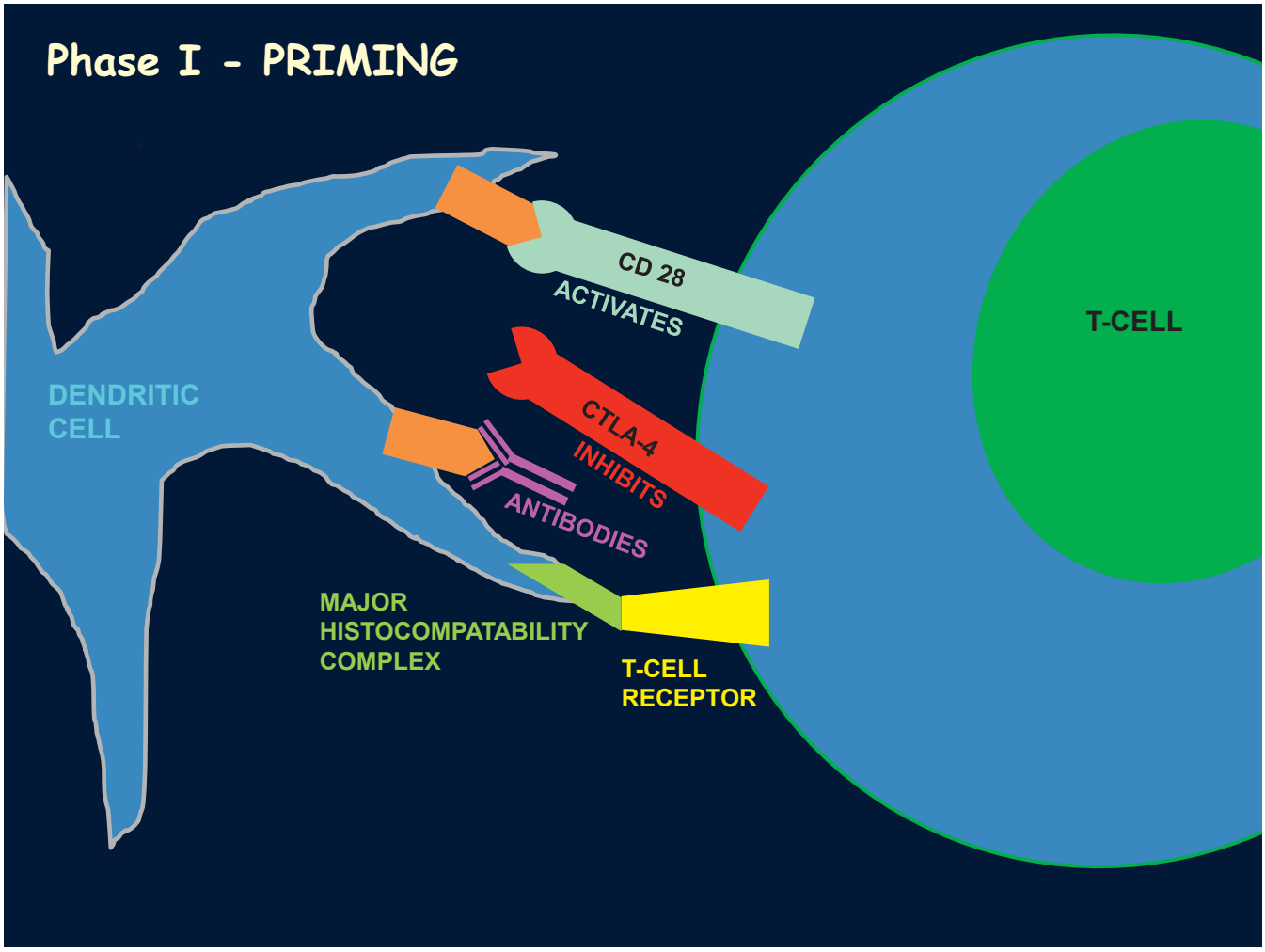
Phase I - PRIMING
CD 28
ACTIVATES
T-CELL
DENDRITIC
CELL
CTLA-4
INHIBITS
ANTIBODIES
MAJOR
HISTOCOMPATABILITY
COMPLEX
T-CELL
RECEPTOR

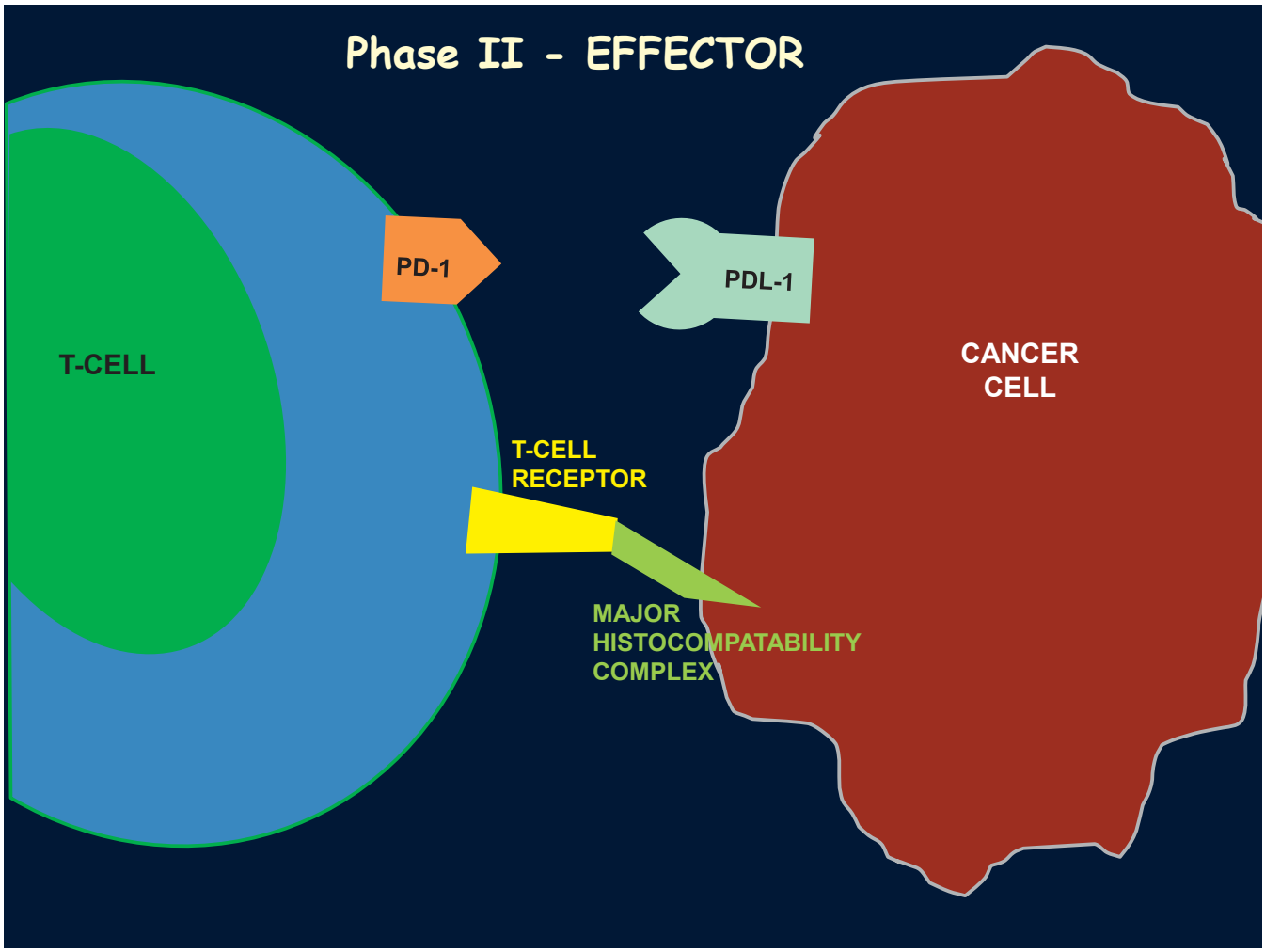
Phase II - EFFECTOR
PD-1
PDL-1
T-CELL
CANCER CELL
T-CELL RECEPTOR
MAJOR HISTOCOMPATABILITY COMPLEX

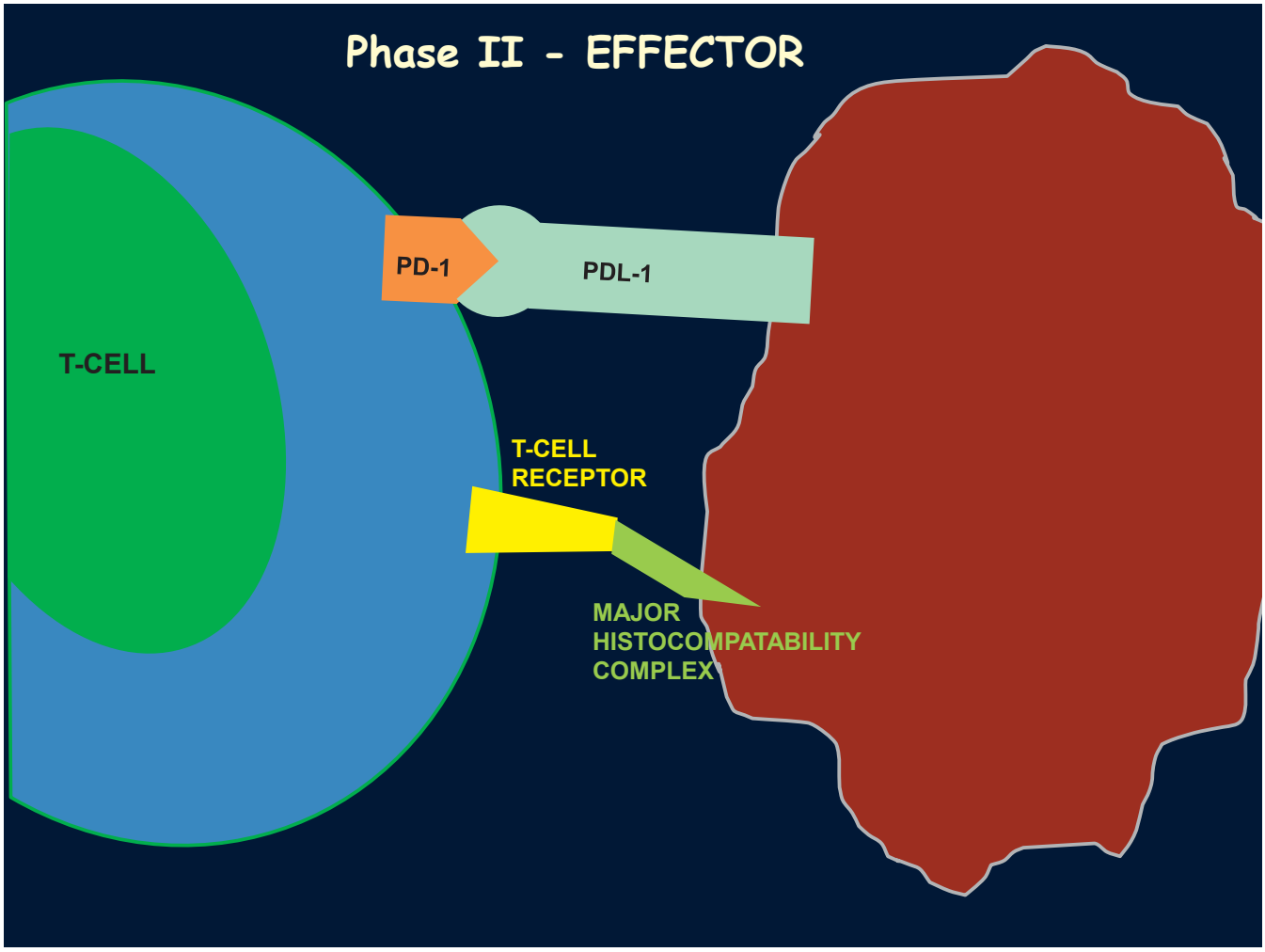
Phase II - EFFECTOR
PD-1
PDL-1
T-CELL
T-CELL RECEPTOR
MAJOR HISTOCOMPATABILITY COMPLEX

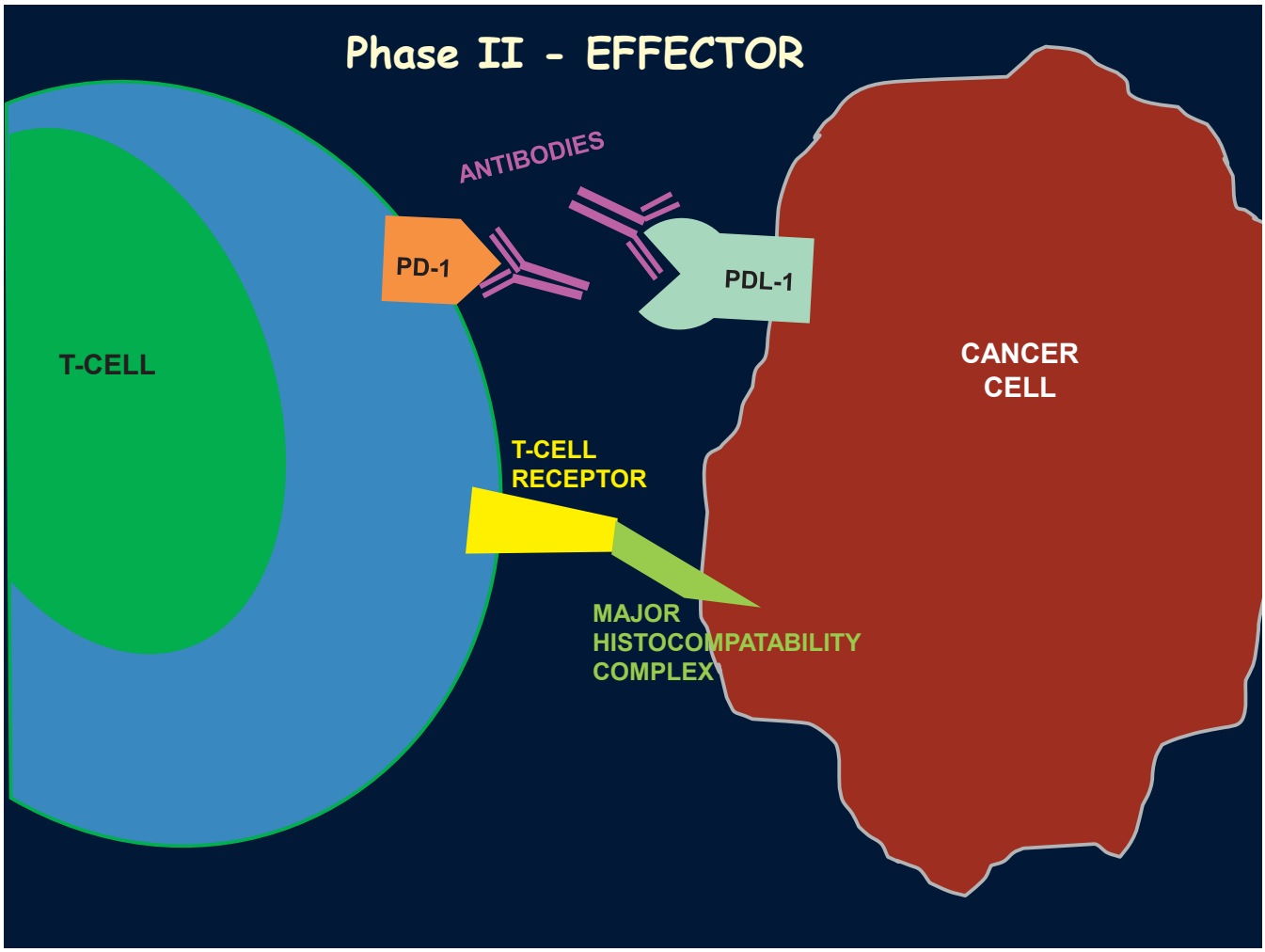

Immunology Wars

https://www.youtube.com/watch?v=5AXApBbj1ps

Case 2: Mrs. T

- Diagnosed with metastatic melanoma six weeks ago.
- Four weeks ago, started on a combination of nivolumab (a PD-1 inhibitor) and ipilimumab (a CTLA-4 inhibitor)
- Presents to your office complaining of an itchy, bumpy and red rash of the neck, anterior chest and upper back that started about a week ago
- In the past two days she has noticed the emergence of increasingly itchy, similar lesions more diffusely across the chest, back, waist and extremities
- Some difficulty sleeping and concentrating at work.
- No history of allergies; no exposures to similar rashes

Dermatitis and Immune Checkpoint Inhibitors

Large variety, from minor to serious

From itch, without rash, to life-threatening

Dermatologic Immune-Related Adverse Events

- inflammatory reactions such as morbilliform rash

Creative Commons Attribution-NonCommercial-NoDerivs 3.0 (New Zealand
at https://creativecommons.org/licenses/by-nc-nd/3.0/nz/legalcode

Dermatologic Immune-Related Adverse Events

- Psoraisiform rashes

Creative Commons Attribution-NonCommercial-NoDerivs 3.0 (New Zealand
at https://creativecommons.org/licenses/by-nc-nd/3.0/nz/legalcode

Dermatologic Immune-Related Adverse Events

- Lichenoid reactions

Creative Commons Attribution-NonCommercial-NoDerivs 3.0 (New Zealand
at https://creativecommons.org/licenses/by-nc-nd/3.0/nz/legalcode

Dermatologic Immune-Related Adverse Events

- Immunobullous lesions resembling dermatitis herpetiformis or bullous pemphigoid

Creative Commons Attribution-NonCommercial-NoDerivs 3.0 (New Zealand
at https://creativecommons.org/licenses/by-nc-nd/3.0/nz/legalcode

Dermatologic Immune-Related Adverse Events

- Acantholytic dyskeratosis

Creative Commons Attribution-NonCommercial-NoDerivs 3.0 (New Zealand
at https://creativecommons.org/licenses/by-nc-nd/3.0/nz/legalcode

Dermatologic Immune-Related Adverse Events

- Immunologic attack on melanocytes
  (halo nevi, regression of nevi,
  tumoural melanosis and vitiligo)

Creative Commons Attribution-NonCommercial-NoDerivs 3.0 (New Zealand
at https://creativecommons.org/licenses/by-nc-nd/3.0/nz/legalcode

Case 2: Mrs. T (continued)

- On examination, the majority of the her skin is affected by an erythematous maculopapular morbilliform rash
- Heaviest on the upper chest, upper back, waist and proximal extremities, less on abdomen and distal extremities
- You estimate it covers 70 – 80% of her skin surface
- No pustules
- No lip or tongue swelling
- No vesicles or bullae
- Oral mucosa and conjunctiva look normal
- No lesions of the palms or soles

Grading Dermatological Toxicity

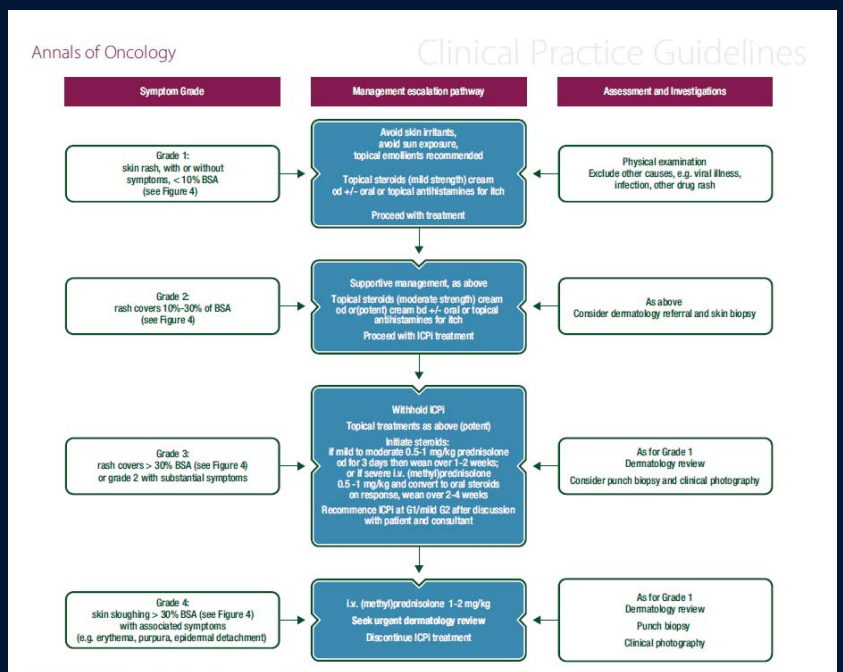

Figure 3. ICPi-related toxicity: management of skin rash/toxicity.
Recognised skin AEs include: (i) most common: erythema, maculopapular and pustulopapular rash; (ii) rare: toxic epidermal necrolysis, Steven-Johnson syndrome and DRESS; (iii) vasculitis may also be present with purpuric rash.
AE, adverse event; bd, twice daily; BSA, body surface area; DRESS, drug rash with eosinophilia and systemic symptoms; ICPi, immune check-point inhibitor; i.v., intravenous; od, once daily.

Haanen JBAG, et.al. Management of toxicities from immunotherapy: ESMO Clinical Practice Guidelines for diagnosis, treatment and follow-up. Annals of Oncology 2017;28 (Supplement 4): iv119–iv142.

Case 2: Mrs. T (Management)

- Grade 2-3 dermatitis
- Contact her oncologist / treatment team
- Hold treatment with “ipi-nivo”
- Consider urgent dermatology consult / biopsy
- Consider steroids – e.g. Prednisone 1 mg/kg/day
- Work out a plan in collaboration with the consultants for the reassessment of the patient and monitoring for response to therapy
- Steroid tapering needs to be individualized, is usually very slow, and should be done in close consultation with the involved specialists.

Timing of occurence of immune-related adverse events following ipilimumab treatment

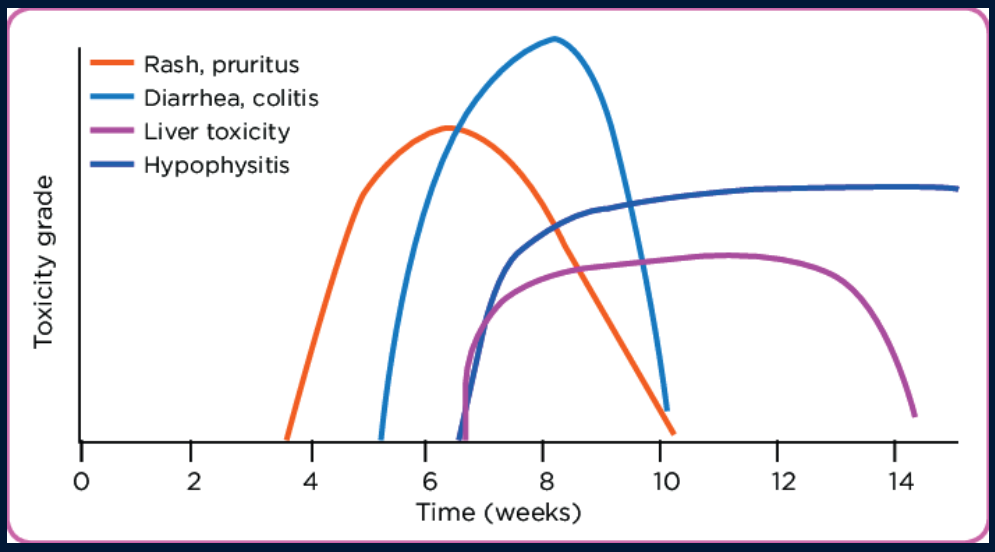

Haanen JBAG, et.al. Management of toxicities from immunotherapy: ESMO Clinical Practice Guidelines for diagnosis, treatment and follow-up. Annals of Oncology 2017;28 (Supplement 4): iv119–iv142.

Time to onset of Grade 3-4 treatment-related selected adverse events

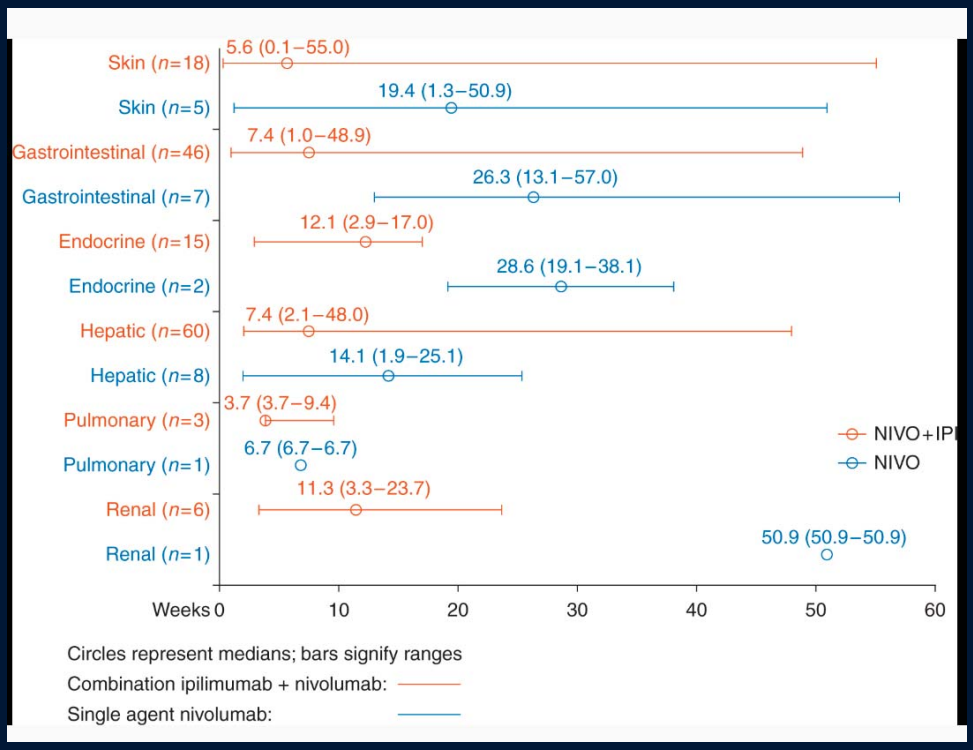

Haanen JBAG, et.al. Management of toxicities from immunotherapy: ESMO Clinical Practice Guidelines for diagnosis, treatment and follow-up. Annals of Oncology 2017;28 (Supplement 4): iv119–iv142.

Grading Gastrointestinal Toxicity

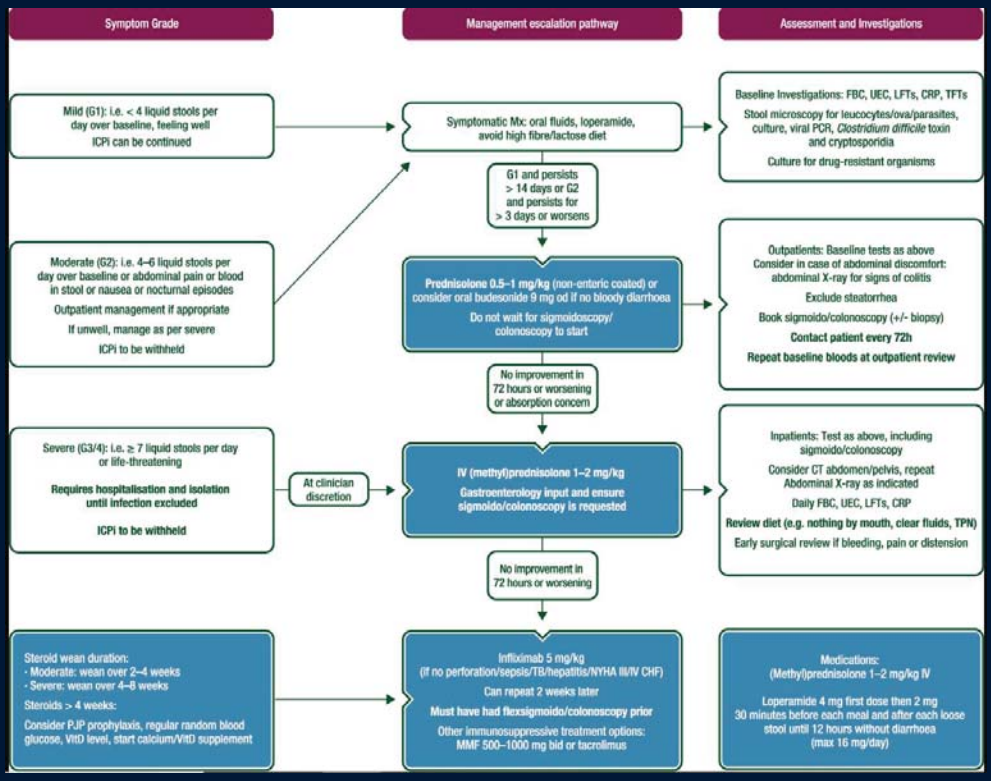

Haanen JBAG, et.al. Management of toxicities from immunotherapy: ESMO Clinical Practice Guidelines for diagnosis, treatment and follow-up. Annals of Oncology 2017;28 (Supplement 4): iv119–iv142.

Case 3: Ms. B

- Presents with diffuse, crampy abdominal pain in association with increasingly frequent passage of loose-to-watery stools.
- Diagnosed with a Stage IV melanoma twelve weeks ago
- PET/CT showed a lung lesion
- Began treatment 8 weeks ago with pembrolizumab
- Five weeks ago (three weeks into treatment) she was seen at a walk-in clinic complaining of diffuse itching, and was prescribed hydroxyzine 10 mg TID and hydrocortisone 1% cream, with partial benefit. At that visit she was also prescribed cloxacillin for a paronychia.
- Seven weeks into her course of therapy, she noticed an increase in the frequency of her stools, which became loose and watery 3 days ago.

What's in the Differential Diagnosis?

- Immunotherapy toxicity
- Clostridium difficile
- Intercurrent illness

What specifics might you look for on physical exam?

- Mouth ulcers
- Anal lesions such as fistulas, abscesses and fissures
- Tenderness in the epigastrium could suggest immune-related pancreatitis
- Inflammatory changes in the bowel might be confined to the sigmoid and rectum or be distributed in a patchy fashion throughout the lower GI tract.

Case 3: Ms. B (continued)

- Ms. B looks generally well
- HR 92, RR 14, T 36.3, BP 122/78 and SPO2(RA) 96%
- Normal gingiva and normal buccal mucosa
- Lungs are clear to auscultation; heart sounds normal
- Abdomen has moderately increased bowel sounds, mild tenderness in the suprapubic area and the left lower quadrant, but no masses or organomegaly
- Skin exam is unremarkable.

Grading Gastrointestinal Toxicity

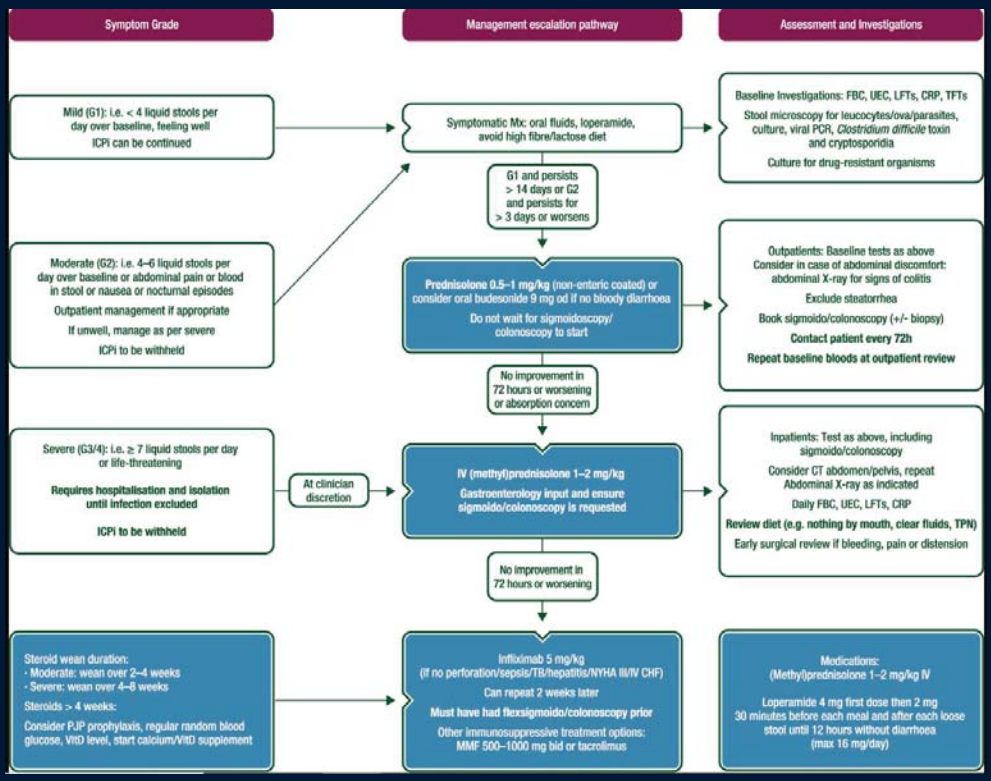

Haanen JBAG, et.al. Management of toxicities from immunotherapy: ESMO Clinical Practice Guidelines for diagnosis, treatment and follow-up. Annals of Oncology 2017;28 (Supplement 4): iv119–iv142.

Case 3: Ms. B (Management)

- Grade 2 diarrhea
- Contact her oncologist / treatment team
- Hold treatment with pembrolizumab
- Stool for cultures and C. difficile toxin
- If worsens, may require more immunologic testing, consult with gastroenterologist, urgent colonoscopy and biopsies
- Prednisone 1 mg/kg may be advised
  - NOTE: SLOW TAPER
- FOLLOW UP

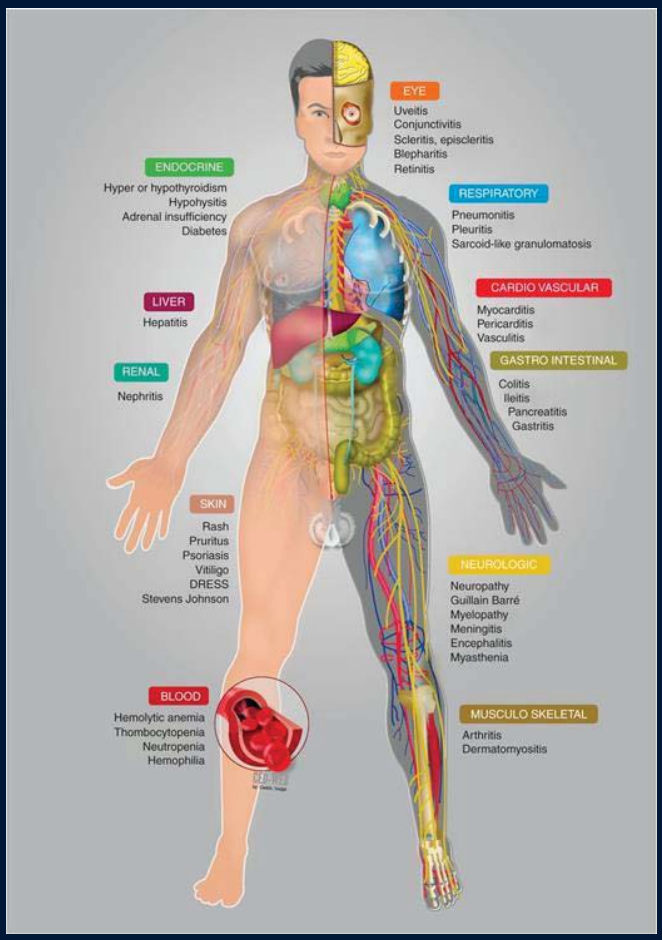

The Spectrum of Immune-Related Adverse Events Related to Immune Checkpoint Inhibitors

Champiat, et.al. Management of immune checkpoint blockade dysimmune toxicities: a collaborative position paper. Annals of Oncology 2016;27:559–574.

"All the side effects
Are these drugs worth it?"

Survival Outcomes in Patients With Previously Untreated *BRAF* Wild-Type Advanced Melanoma Treated With Nivolumab TherapyThree-Year Follow-up of a Randomized Phase 3 Trial.

Ascierto PA, et.al. *JAMA Oncol.* 2019;5(2):187-194.

- 418 patients enrolled January 2013 - February 2014
- 18 years or older with confirmed unresectable previously untreated stage III or IV melanoma ECOG perf status 0/1
- Randomized to nivolumab or dacarbazine

Survival Outcomes in Patients With Previously Untreated *BRAF* Wild-Type Advanced Melanoma Treated With Nivolumab TherapyThree-Year Follow-up of a Randomized Phase 3 Trial.

Ascierto PA, et.al. *JAMA Oncol.* 2019;5(2):187-194.

- 3-year overall survival: were 51.2%(N) vs 21.6%(D)
- Median survival: 37.5 months(N) vs 11.2 months(D)
- Survival in the nivolumab group ranged from 25.5 months to still alive at the end of the 3-year study
- Complete response: 19%(N) vs 1.4%(D)
- Partial response: 23.8%(N) vs 13.0%(D)
- Treatment related grade 3/4 adverse events:

  15%(N) vs 17.6%(D)
- No deaths due to study drug toxic events

Case 1 – Mr. G

- May 2018 – Pembrolizumab IV q3weeks

- January 2019 – No evidence of metastatic disease !

Stay tuned for more T-cell stimulation!

Summary

1. The immune system is inherently involved in cancer control
2. Specific agents block naturally occurring immune checkpoints, increasing immune effects
3. Immune system stimulation causes a potential excessive immune response that can affect a number of systems
4. Immune side effects may be mild or serious
5. Early recognition, and early intervention are key components to effective management of immune effects
6. Ask for help earlier rather than later

Resources / Further Reading

- Dong H, Markovic SN, Editors. The Basics of Cancer Immunotherapy. Springer International Publishing AG 2018. ISBN 978-3-319-70621-4
- Finn OJ. Immuno-oncology: understanding the function and dysfunction of the immune system in cancer. Annals of Oncology 2012;23 (Supplement 8): viii6–viii9. Available at: https://academic.oup.com/annonc/article/23/suppl_8/viii6/185182
- Brahmer JR, et.al. Management of Immune-Related Adverse Events in Patients Treated With Immune Checkpoint Inhibitor Therapy: American Society of Clinical Oncology Clinical Practice Guideline. J Clin Oncol 36:1714-1768. Available at: http://ascopubs.org/doi/pdf/10.1200/JCO.2017.77.6385
- Haanen JBAG, et.al. Management of toxicities from immunotherapy: ESMO Clinical Practice Guidelines for diagnosis, treatment and follow-up. Annals of Oncology 2017;28 (Supplement 4): iv119–iv142. Available at: https://academic-oup-com.uml.idm.oclc.org/annonc/article/28/suppl_4/iv119/3958159