27th Annual Rural and Remote Medicine Course
APRIL 4-6, 2019
HALIFAX CONVENTION CENTRE
Halifax, Nova Scotia

DIAGNOSIS AND MANAGEMENT OF PALPITATIONS AND SYNCOPE IN THE PAEDIATRIC POPULATION / CHILDREN'S ECG FINDINGS

Santokh S. Dhillon MD, FRCPC
Pediatric Cardiologist / Electrophysiologist
IWK Health Centre
Assistant Professor, Department of Pediatrics
Dalhousie University, Halifax

Case 1

- 12 y/o girl recurrent syncopal episodes
- She was watching a movie, felt hot, sweaty, stood up, tried to lay down on bed, collapsed on the floor , awake by the time her mom came in few seconds, no pulse check, felt exhausted, looked pale afterwards, seen in ER
- ADHD on Strattera 40 mg OD
- Negative FHx
- Normal Examination

ECG

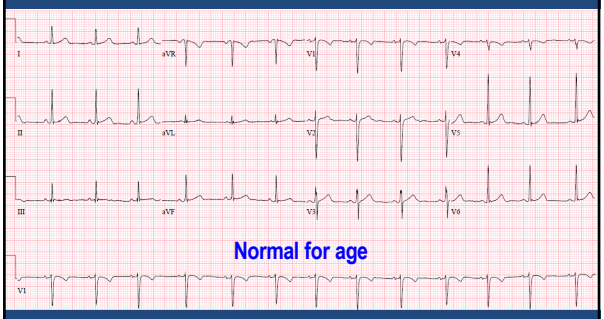

Syncope

"a symptom not a diagnosis"

- An abrupt, transient, complete loss of consciousness
- Inability to maintain postural tone
- Rapid and spontaneous recovery
- No clinical features of other causes of loss of consciousness (seizure, head trauma, or apparent loss of consciousness (i.e., pseudosyncope)

Presumed mechanism is cerebral hypoperfusion

2017 ACC/AHA/HRS Guidelines

Syncope

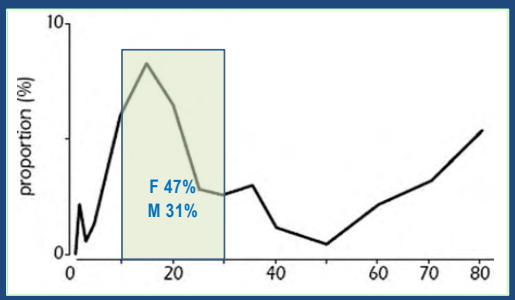

Age at first episode

1% toddlers have some VVS

ESC guideline 2009

Transient loss of conscious in children

Cause	Incidence %
Vasovagal	64-73
Breath holding	6.4
Cardiac syncope	2.9-4.8
Neurogical	2.1-4.6
Metabolic	0.8
Psychiatric	2.2-2.3
Unknown	8.2-18.9

Zhang etal; Acta Paediatr 2009
Raucci etal; J Pediatr 2014
CCS statement 2016

Neurocardiogenic or Vasovagal syncope

- Upright posture held for more than 30 seconds
- Exposure to emotional stress, pain, or medical settings
- Diaphoresis, warmth, nausea, and pallor
- Hypotension and relative bradycardia, when known
- Followed by fatigue

HRS consensus statement; Heart Rhythm 2015

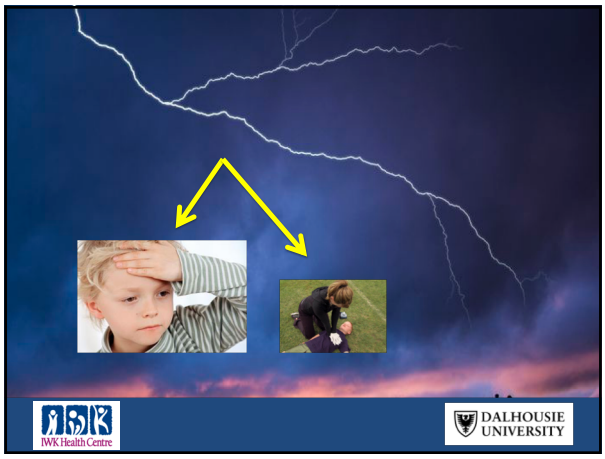

"Diagnostic approach is a challenge"

- Transient loss of consciousness
- Episodic, asymptomatic in clinic, unwitnessed, and anxiety
- Diminished quality of life
- 25% inappropriate admission rate
- Probable diagnosis in 75% of pts on initial evaluation

ESC Guidelines 2009

Approach

- History
- Physical examination
- ECG
- Echocardiogram
- Long term rhythm monitoring
- Exercise test
- Advanced imaging
- Tilt table test
- Electrophysiological study

Approach

- History
- Physical examination
- ECG
- Echocardiogram
- Long term rhythm monitoring
- Exercise test
- Advanced imaging
- Tilt table test
- Electrophysiological study

History

- Most valuable tool
- Diagnosis established in 50-85% cases

6Ps:

Patient characteristics
Predisposing factors
Prodromal symptoms
Pre-existing conditions
Presentation
Post episode

Patient characteristics

Age

< 5 years

Older children/adolescents

Sex

Know cardiac disease

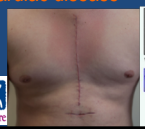

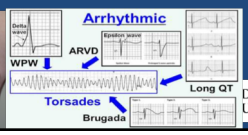

IWK Health Centre

DALHOUSIE UNIVERSITY

Prodrome

Longer and pronounced Neurocardiogenic symptoms

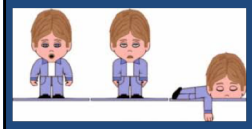

No or minimal prodrome Palpitations

Posture

Standing or change from sitting to standing

Supine or sitting

IWK Health Centre

Chen etal; Acta Paediatr 2007

DALHOUSIE UNIVERSITY

Pre-existing medical condition

- Hyperventilation/anxiety with psychiatric illness
- Autonomic neuropathy with diabetes, dysautonomia
- Medications
- Family History: sudden cardiac death, premature cardiac death, congenital heart diseases

IWK Health Centre

Yang J etal; Cardiology young 2013
Ikiz MA etal; Pediatr Emerg Care 2014
CCS position statement 2016

DALHOUSIE UNIVERSITY

Predisposing factors

Red flags



IWK Health Centre

Yang J etal; Cardiology young 2013
Ikiz MA etal; Pediatr Emerg Care 2014
CCS position statement 2016

Syncope in a church is not from

IWK Health Centre

DALHOUSIE UNIVERSITY

Presentation

- Collateral history:
  - Onset, way of falling, skin color, duration of LOC, breathing pattern, tongue biting
  - Abnormal movements, relation with LOC
  - Associated symptoms/signs
  - Duration of symptoms
- Number of episodes and time from first episode to subsequent episodes

IWK Health Centre

Yang J etal; Cardiology young 2013
Ikiz MA etal; Pediatr Emerg Care 2014
CCS position statement 2016

DALHOUSIE UNIVERSITY

Post episode

- Quick recovery with persistence of nausea, pallor, and diaphoresis suggests neurocardiogenic
- Delayed with persistent neurologic changes and confusion suggests CVA/seizure

Yang J. etal: Cardiology young 2013
Ikiz MA etal; Pediatr Emerg Care 2014
CCS position statement 2016

Physical examination

- Rarely helpful
- HR, O2 saturation, BP, Orthostatic changes
- Complete cardiac and neurological examination
- Red flags:
  - Cyanosis
  - Pathologic murmur
  - Pulse volume discrepancy
  - Sternotomy scar
  - Persistent neurological deficit

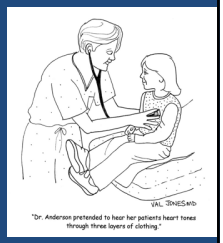

CCS Position statement 2016
Paris etal; JAHA 2016

Investigations

- EEG, Neuroimaging for atypical syncope (SR-LQE)
- For children who present with a history typical of VVS, no family history of epilepsy, and normal physical examination:
  - No further EEG, neuroimaging or cardiac investigations recommended

ACC/AHA/HRS Guidelines 2017

Red flags :Cardiac syncope

- Male sex
- Personal or family history of cardiac disease
- No or minimal prodrome
- Palpitations at times of syncope
- Mid exertional syncope
- Supine/sitting posture
- Traumatic injury
- History of arrhythmia
- Abnormal PE
- Abnormal ECG

ACC/AHA/HRS Guidelines 2017
Massin etal; Clin Cardiol 2007
Hurst etal; The Journal of Emergency Medicine 2015

Pathophysiology of vasovagal syncope

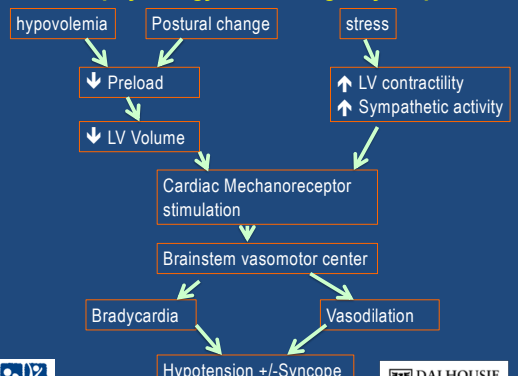

Treatment of vasovagal syncope in children

- Recommend a conservative strategy (SR, LQE)
  - Education
  - Avoidance of provoking factors
  - Increase in salt and fluid intake
  - Teaching physical maneuvers as a preventative and rescue strategy
- Midodrine: In active hours recommended for highly symptomatic children resistant to conservative measures (SR, LQE)
- BB and Fludrocortisone showed contradictory effects

CCS Position Statement 2016

Physical countermaneuvers

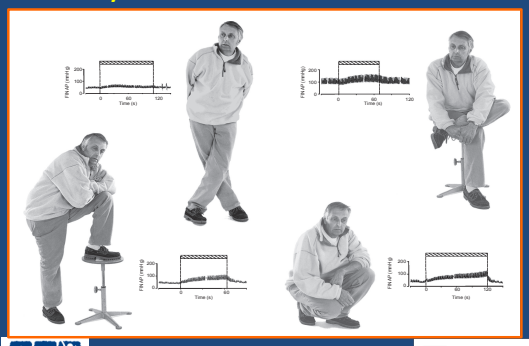

Wieling etal; J of Int Med 2014

Suggested plan for children & adolescents

CCS Position Statement 2016

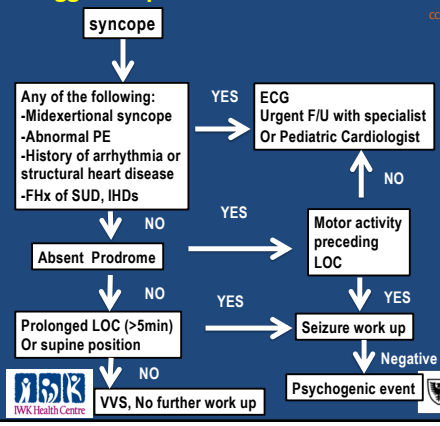

Case 2

- 4 y/o male presented with SOB. In ER while sitting and having blood work , he passed out, he looked pale and was limp, no premonitory signs or crying. He came around quickly after laying down and with some sugar.
- No significant family history
- No medication
- PE: Heart murmur

ECG

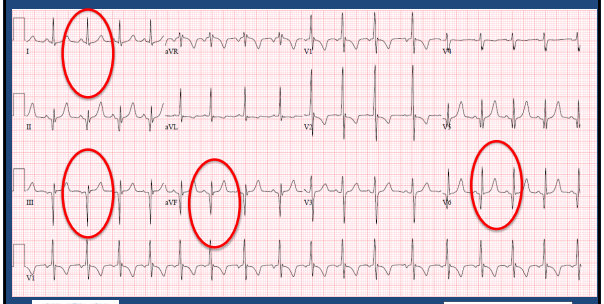

Echo: Hypertrophic cardiomyopathy

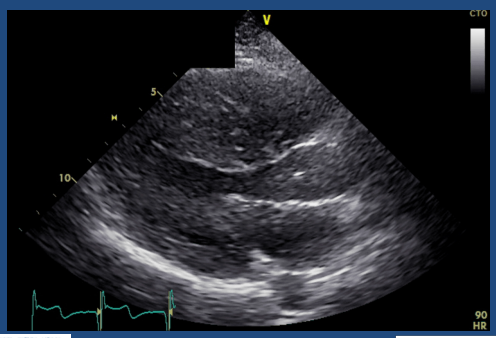

Case 2

- 4 y/o male presented with SOB. In ER while sitting and having blood work , he passed out, he looked pale and was limp, no premonitory signs or crying. He came around quickly after laying down and with some sugar. No post-ictal lethargy/ fatigue.
- No significant family history
- No medication
- PE: Heart murmur

Syncope in HCM

- *Unexplained syncope <18 yr , Hazard ratio 8 for SCD*
- *Recent (with 6 month) unexplained syncope, 5 fold increase risk of SCD vs no syncope*

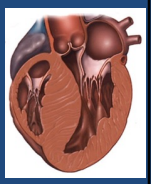

Spirito P etal; Circulation 2009

Case 3

- 8 y/o healthy girl collapsed while dancing and running on New Year eve
- No limb movements, no bowel/bladder incontinence, looked pale/greyish
- FHx: Mother/Maternal uncle with abnormal ECG
- CPR by bystander aunt before paramedic's arrival.
- Monitor showed polymorphic VT, defibrillated, total CPR time 20 mins.
- Quick neurological recovery, Brain MRI reassuring.

ECG at presentation

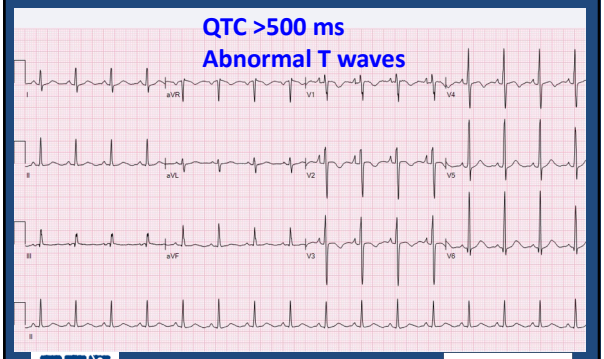

Triggers for cardiac events in LQTS

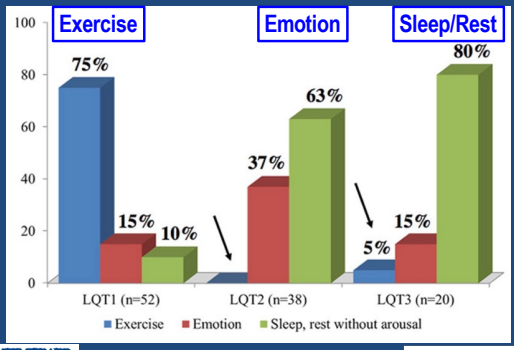

Schwartz Circulation 2001

Suspect cardiac cause:

- Male sex
- Personal or family history of cardiac disease
- No or minimal prodrome
- Palpitations at times of syncope
- Mid exertional syncope
- Supine/sitting posture
- Traumatic injury
- History of arrhythmia
- Abnormal PE
- Abnormal ECG

ACC/AHA/HRS Guidelines 2017
Massin etal; Can.Cardiol 2007
Hurst etal; The Journal of Emergency Medicine 2015

ECG in syncope

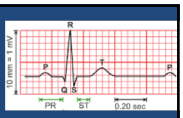

- Low yield & Specificity in acute setting
- **ECG recommended (SR, LQE) if:**
  - History is not diagnostic of vasovagal syncope
  - No prodrome before syncope
  - Midexertional event (eg, swimming)
  - Syncope triggered by loud noise or startle
  - FHx of sudden death or heart disease in young individuals
  - Abnormal cardiac examination
  - New medication with potential cardiac side effects

CCS Position Statement 2016

ECG
Abnormal corrected QT (Long >470 ms, short < 330 ms)
Type 1 Brugada pattern
Delta wave (ventricular pre-excitation or WPW syndrome)
Myocardial ischemia (ST-T wave changes, Q waves>1 mm)
PVCs, Polymorphic
Third degree heart block
LVH
PVCs, monomorphic
Second degree Av block
HR <40 bpm normally nourished , non-athletic individual
Sinus arrhythmia
Wandering atrial pacemaker
First degree heart block
Negative T waves in right precordial leads
Early repolarization
Incomplete RBBB

Common palpitations

- "Flip-flopping" "Heart is coming out of the chest" feeling of heart stopping and starting again, pounding or flipping sensation
- Usually with PACs, PVCs

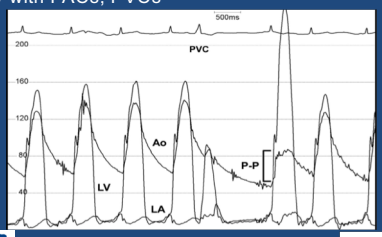

Zimetbaum & Josephson, NEJM 1998

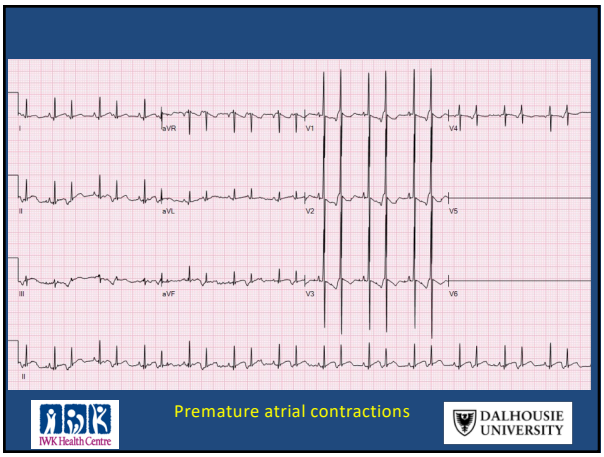

Premature atrial contractions

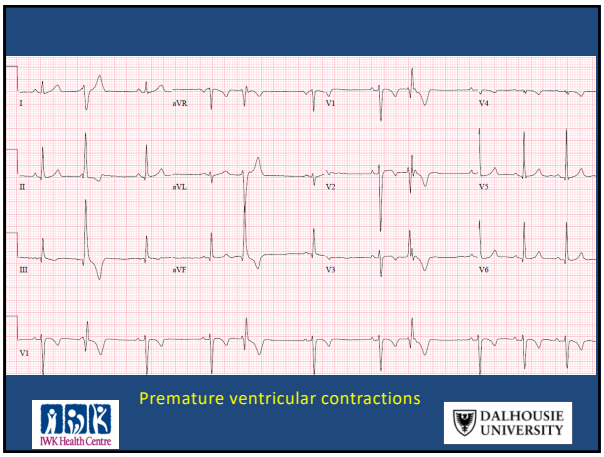

Premature ventricular contractions

Common palpitations

- "Rapid fluttering" "heart is beeping" rhythm may help with the probable mechanism
  - Represents VT/SVT/ST

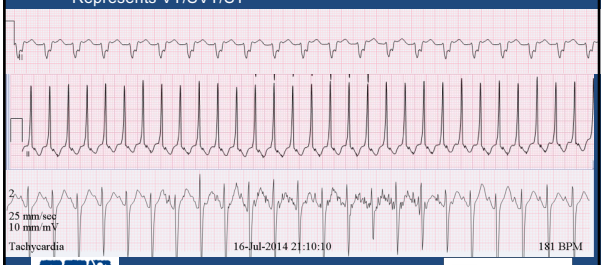

Zimetbaum & Josephson, NEJM 1998

Case 4

- 14 year old healthy athlete boy presented with recurrent palpitations for 2 years, abrupt onset, fast HR, some times associated with pallor and dizziness.
- On concerta
- Unremarkable family history
- Normal examination
- Monitor in ER sinus rhythm, HR 64 bpm

ECG

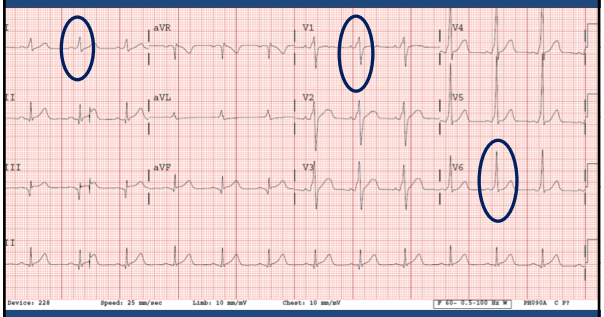

Second episode during hockey play

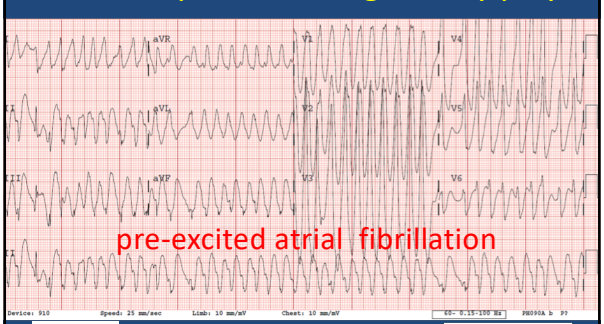

Post ablation

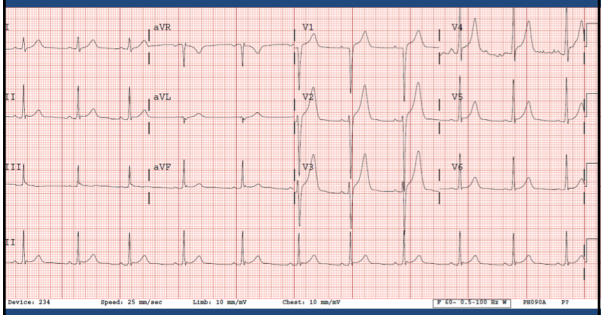

Palpitations: causes

Cardiac

Arrhythmia:
- PACs/PVCs
- SVT/VT
- Bradyarrhythmia (sinus Brady or pause, heart block)

Structural hear disease
- MVP
- Prosthetic valves
- Severe MR/AR
- CHD with significant shunt
- CHF
- Cardiomyopathy (HCM, DCM)

Systemic cause
- Hyperthyroidism, Anemia, fever, orthostatic hypotension
- POTS
- AV fistula
- Pregnancy
- Anxiety/panic attacks, depression

Medications/Drugs
- Sympathomimetics
- Anticholinergic
- BB withdrawal
- Diet pills
- Alcohol, cocaine
- Amphetamines, Caffeine
- Nicotine, cannabis

Palpitations: high risk for arrhythmias

- Structural heart disease unrepaired or repaired
- Channelopathies (Long QT, Brugada syndrome)
- Abnormal ECG
- FHx of SIDS/SCD/Arrhythmias
- Palpitations associated with hemodynamic compromise
- Tachycardic palpitations

Rhythm –symptom correlation

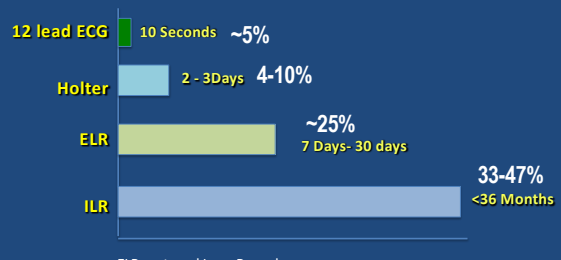

ELR= external Loop Recorders
ILR=Implantable Loop recorders

Linzer M Ann Intern Med 1997
Linzer M Am J Cardiol 1990
Brown; Br Heart J 1987

Case 5

- 15 year old girl had 4 episodes of syncope
- First 2 episodes (3 wks apart) felt palpitations & dizzy on beginning of dance. She fell backwards, lost consciousness and bladder control.
- Recovered spontaneously, headache and tiredness afterwards.
- 3rd episode occurred 6 weeks later during running, felt dizzy & palpitations, fell on face and lost consciousness for few minutes. She recovered spontaneously. Normal evaluation and ECG in ER.
- 1 year later at family gathering she began to dance, felt palpitations, sat down and leaned forward and lost consciousness.
- Family physician friend could not find pulse. She recovered spontaneously in a minute.
- Called cardiology, booked for Echo/Holter/EST

IWK Health Centre | DALHOUSIE UNIVERSITY

ECG

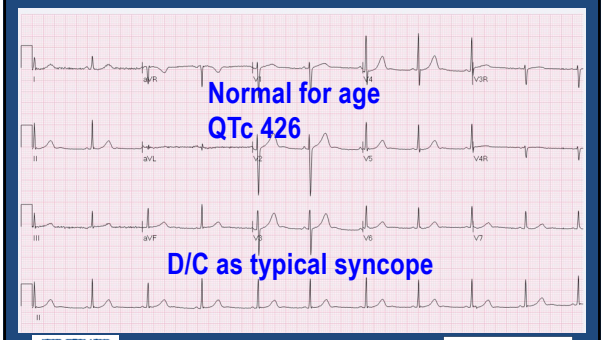

IWK Health Centre | DALHOUSIE UNIVERSITY

Holter: PACs, Echo: Normal
Exercise test

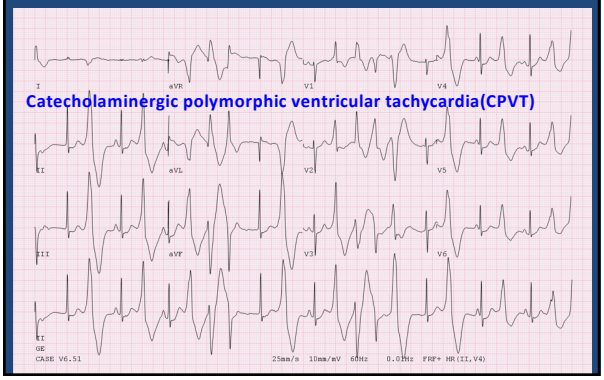

Red flags :Cardiac syncope

- Male sex
- Personal or family history of cardiac disease
- No or minimal prodrome
- Palpitations at times of syncope
- Mid exertional syncope
- Supine/sitting posture
- Traumatic injury
- History of arrhythmia
- Abnormal PE
- Abnormal ECG

IWK Health Centre | ACC/AHA/HRS Guidelines 2017, Massin etal; Clin.Cardiol 2007, Hurst etal; The Journal of Emergency Medicine 2015 | DALHOUSIE UNIVERSITY

Red flags :Cardiac syncope

- Male sex
- Personal or family history of cardiac disease
- No or minimal prodrome
- Palpitations at times of syncope
- Mid exertional syncope
- Supine/sitting posture
- Traumatic injury
- History of arrhythmia
- Abnormal PE
- Abnormal ECG

IWK Health Centre | ACC/AHA/HRS Guidelines 2017, Massin etal; Clin.Cardiol 2007, Hurst etal; The Journal of Emergency Medicine 2015 | DALHOUSIE UNIVERSITY

History and Physical Findings	RED LIGHT Recommend Urgent Referral to Syncope Specialist	YELLOW LIGHT Consider Further Investigations or Semi-urgent Referral to Syncope Specialist	GREEN LIGHT Reassuring for Nonserious Cause; No Further Investigation Required
Hydration status and timing of most recent meal			Missed meals, poor fluid intake
Environmental conditions	Syncope triggered by loud noise-look for long QT and refer if ECG positive		Painful stimulus, sight of blood, very warm environment
Activity preceding the syncopal event	Midexertional syncope (consider cardiac causes) Syncope while swimming (might be associated with LQTS)		Postexertional syncope Prolonged standing
Use of drugs and medications		Medications that may prolong QT (refer if ECG abnormal)	No medications
Prodrome	No prodrome (concerning for arrhythmia)	Short or atypical prodrome	Warmth, nausea, light-headedness, a visual grey-out or tunneling of vision
Other symptoms		Acute chest pain followed by syncope Palpitations just before syncope	
Position of child preceding event		Supine (consider seizure)	Prolonged or recent standing Position change from seated or lying to standing
Duration of loss of consciousness		Prolonged > 5 minutes (consider seizure or somatization)	Short; < 1-2 minutes
Movement during event	Tonic-clonic movements or motor activity preceding LOC (consider seizure)	Exaggerated or flailing movements (consider somatization)	Myoclonic jerks after loss of consciousness
History (previous syncopal events, cardiac disease, diabetes, seizures, and psychiatric or psychological problems)	Arrhythmia, structural heart disease Seizures	Diabetes Psychiatric disorder or medications Significant comorbidities	No relevant medical history Previous events consistent with vasovagal syncope or breath-holding spells
Family history (structural cardiac disease, arrhythmias, sudden death, migraines, or seizures)	Sudden death Arrhythmias	Seizures Structural heart disease	Vasovagal syncope Migraines
Focused cardiac and neurologic examinations	Pathologic murmur Sternotomy scar Persistent neurologic deficits (consider stroke, seizure, migraine)		Normal examination Typical flow murmur

IWK Health Centre | CCS Position Statement 2016 | DALHOUSIE UNIVERSITY

Take home message

- Syncope and palpitations in children are usually benign except if it occurs during exertion, without any prodrome and associated with known previous cardiac disease.
- Risk stratification of patients is important to the approach.
- Goal is to identify patients having or at risk of serious arrhythmias.
- Any atypical presentation of syncope or palpitations or ECG finding, consider consultation with cardiologist.

IWK Health Centre

DALHOUSIE UNIVERSITY

Questions?

IWK Health Centre

DALHOUSIE UNIVERSITY